

UC Irvine

UC Irvine Previously Published Works

Title

Pilot Study of Laser Effects on Oral Mucositis in Patients Receiving Chemotherapy

Permalink

<https://escholarship.org/uc/item/5hz2656d>

Journal

The Cancer Journal, 8(3)

ISSN

1528-9117

Authors

Wong, Siu-Fun
Wilder-Smith, Petra

Publication Date

2002-05-01

DOI

10.1097/00130404-200205000-00008

Copyright Information

This work is made available under the terms of a Creative Commons Attribution License, available at <https://creativecommons.org/licenses/by/4.0/>

Peer reviewed

Pilot Study of Laser Effects on Oral Mucositis in Patients Receiving Chemotherapy

Siu-Fun Wong, PharmD,^a Pomona, California, Petra Wilder-Smith, PhD, DDS,^b Irvine, California

PURPOSE

The purpose of this study was to examine the effectiveness of laser therapy in the prevention and/or healing of chemotherapy-induced oral mucositis lesions. This study also evaluated the ease and feasibility of the laser therapy and the impact of the treatment on improving the patient's quality of life.

PATIENTS AND METHODS

Fifteen patients with an episode of prior chemotherapy-induced grade 3 or 4 mucositis with 5-fluorouracil continuous infusion consented to participate in this study. All patients were provided with standardized mouth care instructions at the initiation of chemotherapy treatments. Enrolled patients received laser therapy treatments 24 hours before the chemotherapy and then recommenced weekly with evenly distributed exposure to the standardized designated areas by one operator during the entire cycle of chemotherapy at the same doses until the mucositis resolved or the chemotherapy cycle was completed. Intraoral perfusion was measured by laser Doppler technology. Patients were assessed for response to laser therapy according to standardized mucositis grading criteria by evaluating development of lesions, extent and duration of lesions, and time to healing. The effect of laser therapy on ability to continue planned chemotherapy, the reduction in dose, delays, and ability to maintain planned dose intensity were assessed. The impact of laser therapy on pain control was evaluated using the visual analogue score. A quality-of-life survey was completed by each patient at the initiation of chemotherapy and then weekly throughout the chemotherapy.

RESULTS

Eleven of 15 patients experienced grade 0 mucositis, three patients experienced grade 1 to 2 mucositis, and one patient experienced grade 3 to 4 mucositis. Fourteen patients completed the laser therapy as planned, and none of the patients withdrew from the laser therapy treatments because of noncompliance. One patient continued to experience grade 4 mucositis that necessitated an interruption in the planned chemotherapy regimen and, consequently, the laser treatment. Patients tolerated the laser therapy very well and did not report any increased discomfort. No significant changes in perfusion were observed as a result of laser therapy.

DISCUSSION

In this pilot study, laser therapy significantly reduced the incidence and the severity of mucositis in chemotherapy patients. The laser therapy does not appear to promote wound healing by affecting the intraoral perfusion, as assessed by Doppler measurements. The mechanisms involved in the mediating of the observed effects remain unknown at this time. Continued research is warranted to determine the optimal laser wavelength and parameters. (*Cancer J* 2002;8:247-254)

KEY WORDS

Mucositis, low-level laser therapy, 5-fluorouracil continuous infusion

Oral mucositis is manifested as an ulceration of the oral mucosa, which frequently occurs with chemotherapy, when patients may be transiently immunocompromised. Colonization of these ulcerated lesions by indigenous bacteria may lead to septicemia in patients rendered neutropenic by chemotherapy. Presently, few direct measures exist to prevent development or to promote healing of mucositis lesions. Care generally consists of vigorous mouth cleansing, but the oral cavity cannot be fully decontaminated. Thus, care is aimed at symptom control until immune function recovers. Many patients have significant pain requiring narcotic analgesia; subsequently, patients generally experience sub-

From the ^aWestern University of Health Sciences, College of Pharmacy, Division of Hematology/Oncology, Pomona, California, and the ^bBeckman Laser Institute and Medical Clinic, University of California, Irvine, California.

Received on August 17, 2001; accepted for publication November 13, 2001.

No benefits in any form have been or will be received from a commercial party related directly or indirectly to the subject of this article.

Reprint requests: Siu-Fun Wong, PharmD, Western University of Health Sciences, College of Pharmacy, 309 East Second Street, College Plaza, Pomona, California 91766.

Copyright © 2002 Jones and Bartlett Publishers, Inc.

stantial weight loss and nutritional deficits. These complications significantly affect chemotherapy delivery and dose intensity and may ultimately influence treatment response. The development of an active therapeutic intervention that can reduce the morbidity of oral mucositis will improve quality of life, compliance with treatment, and therapeutic outcome.

Low-level laser therapy (LLLT) has been used in humans since the early 1970s. Initially, it was suggested that this form of energy delivery could enhance wound healing.¹⁻⁴ In studies of fibroblast responses to lasers, increased cell division and increased collagen production have been reported.^{5,6} In gingival tissues, low-level laser application stimulated DNA synthesis of myofibroblasts without accompanying degenerative changes and was able to transform fibroblasts into myofibroblasts, which may also promote wound healing.^{7,8} Subsequently, the benefit of low-level energy delivery systems as an anti-inflammatory and pain-reducing tool in both animals and humans was suggested.⁹⁻²² One mechanism postulated for the pain-relieving effects of low-level laser therapy is the modulation of nociception by the modification of nerve conduction via the release of endorphins and enkephalins.²³⁻²⁸ The respiratory chain enzymes within the mitochondria have been identified as the primary receptor chromophores for low-level laser light.²⁹⁻³⁰ Because enzymes are catalysts with the capability of processing large numbers of substrate molecules, they may provide amplification or the initiation of a biologic response with light stimulation.

Several recent publications have reported on LLLT use for the prevention or treatment of chemotherapy-induced mucositis.³⁷⁻⁴¹ Results were significantly better than traditional methods, especially after the preventive use of LLLT. These studies were executed using laser light at 632 nm at energy densities of approximately 0.75–1 J/cm². Although the 630-nm wavelength is within the absorption range of tissue, deeper tissue penetration is achieved with wavelengths of 820–840 nm. The 830-nm beam also provides a very effective output power, thus reducing laser treatment duration—an important factor in the treatment of debilitated patients.

This study examined the effect of laser light at 830 nm on the prevention and healing of oral mucositis lesions and determined the ease of administering such treatment. Additionally, the impact of such therapy on improving the cancer patient's quality of life while receiving chemotherapy was evaluated.

PATIENTS AND MATERIALS

The following investigations were performed after protocol review and approval by the University of California, Irvine Human Subject Review Board.

Patients

Patients 18 years of age or older receiving 5-fluorouracil intravenous continuous-infusion chemotherapy given for malignancy and with a prior episode of mucositis of either grade 3 or 4 per standardized mucositis grading scale (Table 1) were included in these investigations. Continuous infusion 5-fluorouracil was scheduled to be administered for 4 consecutive weeks, followed by a 2-week rest period. Inclusion criteria were a Karnofsky performance status of 50% or higher and a life expectancy of ≥ 2 months. Patients were at least 2 weeks beyond surgery or 4 weeks beyond radiotherapy and other forms of chemotherapy. Patients had recovered from the associated toxicities of surgery, chemotherapy, or radiotherapy. Their granulocyte count measured at least 1500/ μ L, and their platelet count was $\geq 100,000$ / μ L on initiation of laser treatment. Exclusion criteria were concomitant or previous radiotherapy to the head and neck area (i.e., nasopharynx, oropharynx, or larynx), previous surgery for head and neck malignancy, receipt of retinoid therapy at the time of enrollment, wearing of dentures or dental appliances, pregnancy, and absence of a medically accepted form of birth control.

All pretreatment observations were completed within 28 days before laser treatment, when a complete history and physical examination was performed by study-participating physicians and a complete oral examination was performed by study-participating dentists. All patients signed an informed consent before study participation.

Laser Therapy

After an episode of grade 3 or 4 mucositis, enrolled patients were scheduled to receive laser therapy or treatment during subsequent cycles of chemotherapy with the same chemotherapy dosage regimen. Enrolled patients received laser therapy treatments 24 hours before the recommencement of chemotherapy and then weekly throughout the duration of chemotherapy at the same doses until resolution of mucositis or completion of the chemotherapy cycle. Patients wore wavelength-specific dark goggles during the procedure to protect their eyes from exposure to the laser beam. Patients received laser therapy once weekly to deliver a total of 50–60 J with an energy density of approximately 0.7–0.8 J/cm². The laser used was a 70-mW device (Lasermedics Inc., Houston, TX), with a continuous mode of operation and an attached fiberoptic delivery tip. Power emission at the fiberoptic tip measured 45–50 mW (Coherent Field Master Consul laser meter, Coherent Co., Auburn, CA). The laser treatment regimen was provided by one experienced clinician in an effort to standardize the laser irradiation procedure as much as possible. Treatment required

TABLE 1 Mucositis Grading

Grade	Criteria
0	Normal—no mucositis
I	Mild tissue changes (focal) White anemic changes Erythematous patches Mucosal thinning No sensitivity Normal eating
II	Mild tissue changes (focal) Erythematous/thinning mucosa Small ulceration < 2 mm Slight sensitivity Normal eating
III	Moderate tissue changes (focal-diffuse) Erythematous/denuded/ulcerated mucosa < 1/2 mucosal area involved Blood clots—no active bleeding Moderate sensitivity Eating/drinking with difficulty
IV	Marked tissue changes (diffuse) Erythematous/denuded/ulcerated mucosa >1/2 mucosal area involved Active oozing/bleeding Marked pain No eating

Adapted from Toth BB, Fleming TJ. Oral care for the patients with cancer. *Highlights Antineoplastic Drugs* 1990;8:27–35.

15–30 minutes per patient with evenly distributed exposure in each of the following areas: upper labial surfaces, lower labial surfaces, internal surface of left cheek, internal surface of right cheek, dorsal and ventral surfaces of left half of tongue, dorsal and ventral surfaces of right half of tongue, upper left gingival and mucosal quadrant, upper right gingival and mucosal quadrant, lower right gingival and mucosal quadrant, lower left gingival and mucosal quadrant, left side of palate, and right side of palate.

Patient Assessment

Patients were assessed weekly by one prestandardized, experienced clinician. Mucositis was quantified on a scale of 0–4 using the standardized mucositis grading scale (Table 1). Lesion size (approximate area), location, and duration as well as time to healing were also documented. Patients took home seven sheets each week that had a schematic drawing of oral surfaces (Fig. 1). Each day, the patient drew onto this sheet the size, extent, and location of any lesions, having been taught how to do this at the initial visit. Pain was scored daily on a visual analogue scale (VAS) that had a grading scale from 0 (no pain) to 100 (worst possible pain). In addition, effect of laser therapy on the ability to continue planned chemotherapy, reduction in dose delays, and

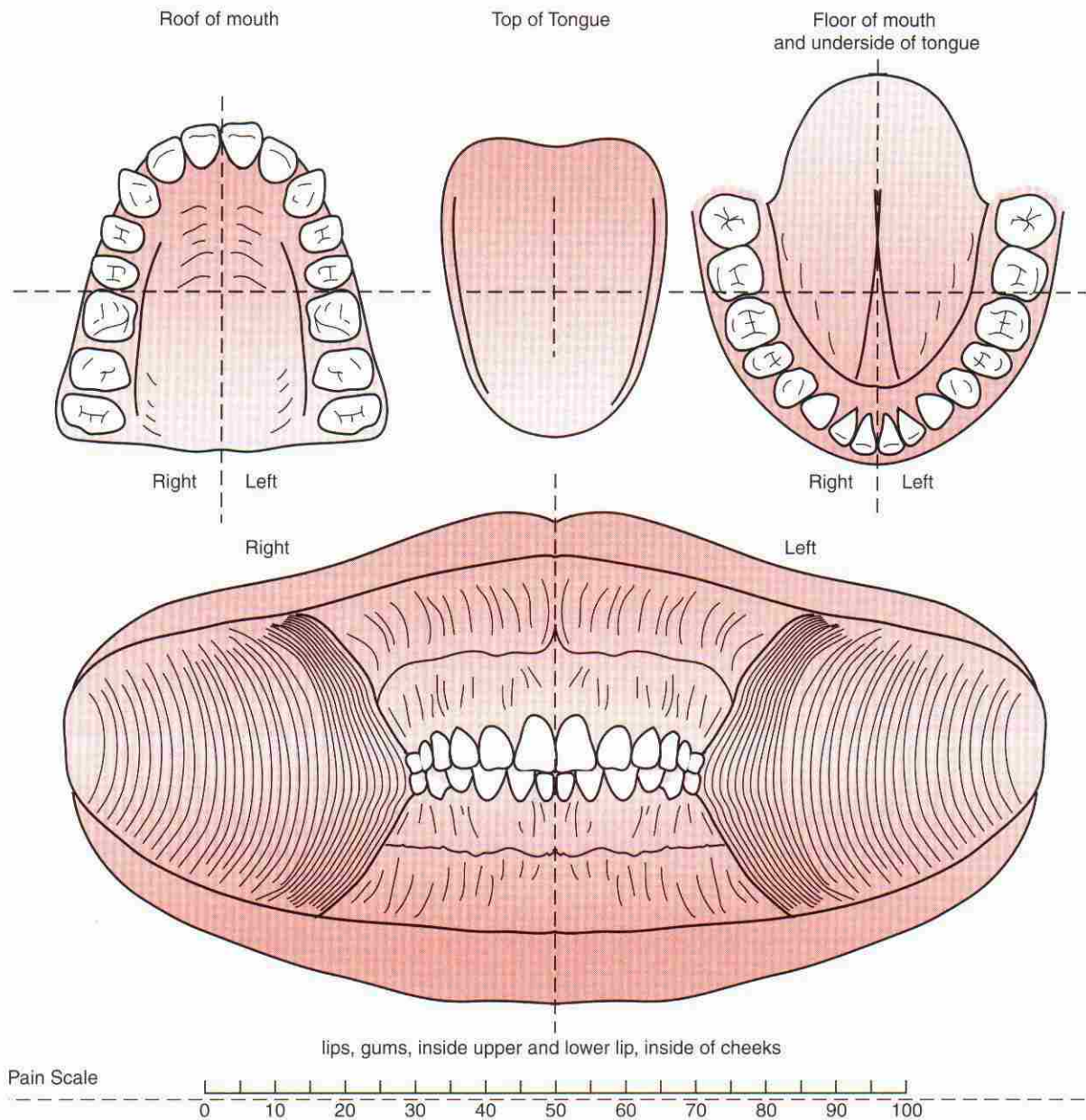
ability to maintain planned dose intensity were assessed. A quality-of-life survey was completed by patients at the initiation of each chemotherapy cycle and then weekly during the entire treatment period. A Karnofsky score was also elicited for each week.

Toxicities to be monitored for the laser device were minimal because this device has been classified as a nonrisk device by the United States Food and Drug Administration. Toxicities secondary to the chemotherapy were monitored and managed according to the standard of medical practice.

Laser Doppler Flowmetry

Laser Doppler flowmetry (LDF) studies were undertaken to provide information on vascular events in the affected areas. All patients underwent measurement of vascularity via LDF weekly, commencing on day 1 of laser treatment. LDF measurements were carried out using the Perimed PF 3 device (Linköping, Sweden) at the following sites before laser therapy and at the completion of the laser treatment:

1. Upper left buccal mucosa: above central incisor, first premolar
2. Lower right buccal mucosa: below central incisor, first premolar



Draw lesions on pictures above. Please draw lesions as close to original size and shape as possible. Also, record date of appearance, date of disappearance, and provide a clear physical description of the lesion.

FIGURE 1 Take home oral health record.

TABLE 2 Visual Analogue Score (VAS) Pain Scores

	Range	Mean (+ SD)	Median	
Baseline	0	0	0	N = 15
Week 1	0-30	4.7 (\pm 8.3)	0	N = 15
Week 2	5-70 ^a	24 (\pm 16)	20	N = 15
Week 3	5-45	17 (\pm 10)	20	N = 14 ^b
Week 4	5-35	18 (\pm 8.5)	18	N = 14 ^b

Abbreviation: SD, standard deviation.

^aThe patient who withdrew from the study due to grade 4 mucositis had the pain score of 70.

^bOne patient withdrew from the study due to grade 3-4 mucositis.

3. Upper right palatal mucosa above central incisor, first premolar; lower left lingual mucosa below central incisor, first premolar
4. Tongue: tip and 1, 2, and 3 cm from tip on left and right side of tongue
5. Cheeks: 1-cm intervals from commissures
6. Inner surface of upper and lower lip between commissures at 1-cm intervals

The LDF probe was fixed in an intraoral custom-made stent to ensure reproducible measurement locations and to prevent probe contact with the oral tissues.

Statistical Analysis

Statistical evaluation was conducted using the Chi-squared test to compare differences between the primary evaluation criterion of the degree of mucositis caused by the same dosage regimen of chemotherapy before and after the low-level laser therapy. Mucositis score at the weekly assessment visits and oral pain assessment (VAS scale scores for each day, averaged over each week) were used as the primary assessment criteria. A separate evaluation was performed of LDF measurements, also using the Chi-squared test.

RESULTS

A total of 15 patients were initiated in the laser therapy. Each patient received a minimum of three and a maximum of seven laser treatments during this study. Before LLLT, all 15 patients had experienced grade 3 or 4 mucositis during chemotherapy. With LLLT, under the same chemotherapy regimen, 11 patients experienced grade 0 mucositis, three patients experienced grade 1–2 mucositis, and one patient experienced grade 3–4 mucositis (Fig. 2). Fourteen patients completed the laser therapy as planned, and none of the patients withdrew from the laser therapy treatments because of noncompliance.

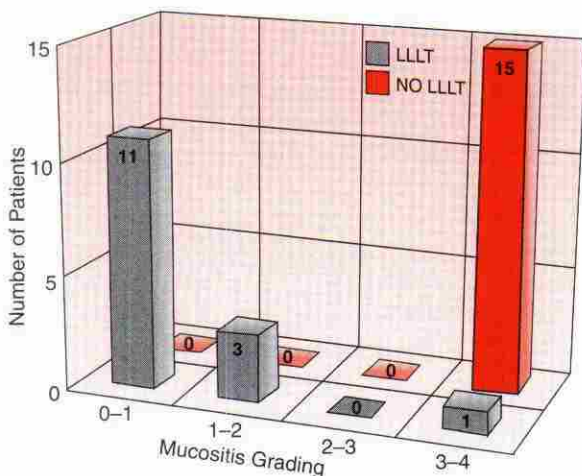


FIGURE 2 Mucositis grading in chemotherapy patients.

One patient continued to experience grade 4 mucositis that necessitated an interruption in the planned chemotherapy regimen and, consequently, the laser treatment. Patients tolerated the laser therapy very well and did not report any increased discomfort due to the laser therapy. Pain scores at baseline and weekly thereafter up to week 4 of LLLT were not significantly different except in one patient, who withdrew from the study because of grade 4 mucositis. This patient had a VAS score of 70 at the time of onset of grade 3–4 mucositis (Table 2).

LDF measurements were taken at a total of 25 locations per patient per visit. The measurements differed markedly from one location to the next and between patients. In any one standard location, no significant changes in intra-oral perfusion were observed as a result of LLLT, as demonstrated by the Doppler measurements general linear procedures: $P < 0.05$) in all 15 patients as shown in Fig. 3.

DISCUSSION

Oral mucositis remains a very problematic adverse effect of radiotherapy and anticancer chemotherapy. Cancer chemotherapy agents, such as alkylating agents, antimetabolites, and antimitotic agents, aim to kill rapidly proliferating cells. Alkylating agents affect the DNA in all phases of the cell cycle to prevent cell reproduction. The antimetabolites block the biosynthetic pathway in the S phase by interfering with the biosynthesis of purines and pyrimidines. The antimitotic agents disrupt the microtubules during metaphase in the M phase. However, chemotherapeutic agents are nonspecific. While destroying malignant cells, they also adversely affect normal host cells with high mitotic indices. The normal cells with a very high rate of proliferation that are adversely affected by chemotherapy particularly include those in oral and gastrointestinal mucosa and the hematopoietic system. Some degree of oral mucositis occurs

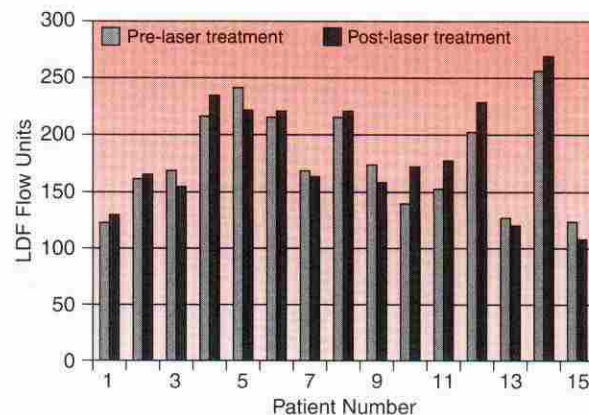


FIGURE 3 Laser Doppler flowmetry (LDF).

in approximately 40% of patients who receive anticancer chemotherapy.⁴² The percentage increases drastically in patients who are treated with localized radiotherapy to the head and neck regions, especially when concurrent chemotherapy is administered and patients may be transiently immunocompromised. Colonization of ulcerated mucositis lesions by indigenous bacteria may lead to systemic infection and septicemia in patients who are rendered neutropenic by chemotherapy. Presently, few direct measures exist to prevent development or promote healing of mucositis lesions. Care generally consists of vigorous mouth cleansing, but the oral cavity cannot be fully decontaminated. Thus, care is aimed at symptom control until immune function recovers. Mucositis is painful, and many patients have significant pain that requires parenteral narcotic analgesia. Mucositis can also limit adequate nutritional intake. Patients generally experience substantial weight loss and nutritional deficits. Mucositis also diminishes patients' quality of life, which may result in serious clinical complications and can decrease the willingness of patients to continue treatment. More severe mucositis with extensive ulceration may require costly hospitalizations with parenteral nutritional support and narcotics. These complications significantly affect radiotherapy and chemotherapy delivery and dose intensity and may ultimately influence treatment response. The development of an active therapeutic intervention, which can reduce the morbidity of oral mucositis, may improve quality of life, compliance with treatment, and therapeutic outcome.

The complete pathophysiology of mucositis continues to be ill defined. On the basis of animal and clinical data, a publication by Pico et al⁴³ attempted to summarize the mechanisms by which mucositis develops and heals, but the outcome remains speculative. In this article, mucositis was described as a four-phase biologic process that involves an inflammatory/vascular phase, an epithelial phase, an ulcerative/microbiological phase, and a healing phase. Each of these phases is independent and is a result of a series of actions mediated by cytokines and other growth factors, the direct effect of the anticancer treatments on the epithelium, the oral microbials, and the status of the immunocompromised host response.

The inflammatory/vascular phase is relatively acute and is caused by the anticancer treatment's causing the release of cytokines (e.g., interleukin-1) from the epithelium and the connective tissue. Cytokines such as tumor necrosis factor and interleukin-1 can cause an inflammatory response that may result in increased subepithelial vascularity.

The epithelial phase is primarily caused by drugs that target the DNA synthesis (S phase of the cell cycle), which are more mucotoxic than other drugs. This phase is documented by the reduction of epithelial renewal,

which results in the production of ulcerative lesions and typically begins about 4 to 5 days after anticancer treatment administration.

The ulcerative/microbiological phase is characterized by the breakdown of mucosal barriers. This phase tends to be most symptomatic and places patients at the highest risk of secondary infection.

The final, healing phase occurs when the renewal of cell proliferation and differentiation allows for return to normal of peripheral blood counts and control of oral microbial flora.

The search for the prevention and treatment of oral mucositis remains a challenge for health care providers. Current treatment options are primarily supportive and are less than optimal. Recent approaches to the prevention and treatment of mucositis induced by anticancer treatments can be primarily categorized according to the specific phase of the biologic process being targeted.

Cryotherapy causing vasoconstriction and temporarily reducing the oral mucosal blood flow has been used to target the initial vascular phase. This therapy has been shown to effectively decrease 5-fluorouracil-induced and melphalan-induced mucositis but only when the drugs are given on short infusions.^{42,44} Cytoprotection using prostaglandin E₂, vitamin E, and β -carotene (a vitamin A precursor) had been investigated, but their roles remain to be determined.^{45,47} Inhibition of factors involved in the cycling of epithelial cells such as transforming growth factor β 3 is being studied. However, the potential of this agent in protecting the proliferating tumor cells against the action of chemotherapy must be ruled out before it is used in the supportive treatment of mucositis.⁴⁸

Several growth factors have been tested to attempt to accelerate the restoration of normal epithelium. Granulocyte colony stimulating factor and granulocyte colony stimulating factor promote the proliferation and differentiation of neutrophils and monocyte/macrophage, and several studies have demonstrated a decrease in the incidence and the severity of mucositis with these agents.^{49,52} A direct effect of granulocyte macrophage colony stimulating factor on the oral mucosa has been demonstrated.⁵³ The cost of this treatment and the optimal time of administration continue to be a challenge for investigators. Keratinocyte growth factor, an epithelial growth factor produced by stroma cells to induce proliferation and differentiation of epithelial cells, is also being evaluated.⁵⁴

Oral glutamine is currently considered to be a promising advancement in the management of oral mucositis. Glutamine is a nonessential amino acid and is a well-known mucosal protector of the bowel. Two studies investigating the role of oral glutamine in reducing chemotherapy-induced oral mucositis revealed positive results.^{55,56} A recent trial showed that gargling with glutamine suspension also reduced both the duration

and the severity of radiation-induced oral mucositis which supports the concept of a local rather than a systemic mechanism for the amelioration of stomatitis.⁵⁷ Oral glutamine is currently being studied by the Southwest Oncology group in the United States to establish its role in the prevention and treatment of mucositis.

The use of oral antimicrobial agents in combination with appropriate oral hygiene to prevent chemotherapy-induced mucositis has provided conflicting data. Studies conducted with lozenges composed of polymyxin B, tobramycin, and amphotericin B provided some encouraging preliminary data.^{58,59} Corticosteroid mouthwash has been reported to shorten treatment interruption of radiation-induced mucositis but did not reduce the intensity or the duration.⁶⁰ Pilocarpine, immunoglobulin, and host defense peptides are still being investigated for their capacity to decrease superinfection.

The mechanistic principles of LLLT remain unclear. However, based on well-documented experimental data, it is clear that the irradiation with low-level laser light can serve as a proliferative stimulus. Effects of LLLT irradiation on the cell cycle include

1. An increase in the number of S-phase cells, connected with enhanced G₁-S transition of a part of the population as well as increased gain count on the labeled nuclei related to enhancement of DNA synthesis in S-phase cells.^{7,8} In addition, there is considerable activation of respiratory chain components—NADH dehydrogenases and cytochrome-c oxidase.^{29,39}
2. A significant increase in the activity of various enzymes. The respiratory chain enzymes within the mitochondria have been identified as the primary receptor chromophores. Because enzymes are catalysts that have the capability of processing large numbers of substrate molecules, they may provide amplification of the initiation of a biologic response with light.^{29,39}

It is possible to conclude that the LLLT can enhance the metabolic process in the cell and activate the proliferation. The experimental data also indicate that the irradiation causes a rearrangement of the cell metabolism, and light only plays a role of trigger. This is the reason that the doses needed for biological effects are comparatively low (10–1000 J/m²) and the irradiation times needed are relatively short (10–100 seconds).

In conclusion, these studies demonstrated the ability of low-level laser therapy to reduce the incidence and the severity of oral mucositis in chemotherapy patients. The laser treatment was well tolerated by patients. On a clinical level, further studies using different laser wavelengths, modes, and energies as well as different irradiation regimens are needed to define optimal treatment parameters. Cellular and molecular investigations are also indicated to define the mechanisms of laser effects.

REFERENCES

1. Mester E, Spiry T, Szende B et al. Effect of laser rays on wound healing. *Am J Surg* 1971;122:532–535.
2. Mester E, Nagylucskay S, Tisza S et al. Stimulation of wound healing by means of laser rays. III. Investigation of the effect on immune competent cells. *Acta Chir Acad Sci Hung* 1978;19:164–170.
3. Mester E, Nagylucskay S, Doklen A et al. Laser stimulation of wound healing. II. Immunological tests. *Acta Chir Acad Sci Hung* 1976;17:49–55.
4. Kovacs IB, Mester E, Gorog P. Laser-induced stimulation of the vascularization of the healing wound: an ear chamber experiment. *Experientia* 1974;30:341–343.
5. Noble P, Shields E, Blecher P et al. Locomotory characteristics of fibroblasts within a 3-dimensional matrix modulation by a He-Ne soft laser. *Laser Surg Med* 1992;12:669–674.
6. Tominaga R. Effects of He-Ne laser irradiation on fibroblasts derived from scar tissue of rat palatal mucosa. *J Stomatol Soc* 1990;57:580–594.
7. Pourreau-Schneider N, Ahmed A, Soudry M et al. Helium-neon laser treatment transforms fibroblasts into myofibroblasts. *Am J Pathol* 1990;37:171–178.
8. Soudry M, Franquin JC, Pourreau-Schneider M et al. Action d'un laser helium-neon sur la croissance cellulaire. *J Bio Buccale* 1988;16:129–135.
9. Goldman JA, Chiapella J, Casey H et al. Laser therapy of rheumatoid arthritis. *Lasers Surg Med* 1980;1:93–101.
10. Soto JM, Moller S. Laser in rheumatology. *Laser Doc Center Bull* 1986;2:15–20.
11. Oyada Y, Satodate R. A double-blind study of low power He-Ne therapy in rheumatoid arthritis. In: Waidelech R, ed. *Laser Photoelectrics in Medicine*. Proceedings of the 7th Congress of the ISLS. San Jose, CA: Wiley, 1987:747–750.
12. Mach FS, Tursrko VV, Lebedeva OI et al. Clinical and instrumental evaluation of the effect of laser therapy in patients with rheumatoid arthritis. *Rheumatologia* 1983;3:36.
13. Mester E, Jaszszagi-Nagy E, Hamar M. The influence of laser radiation on stimulated human lymphocytes. *Radiobiol Radiother* 1974;15:767–769.
14. Simunovic A, Ivankovich AD. Low energy He-Ne + I.R. laser effects on wound healing in animals and human body. *Laser Surg Med* 1988;8:175.
15. Lyons RE, Abergel RP, White RA et al. Biostimulation of wound healing in vivo by a helium-neon laser. *Ann Plast Surg* 1987;18:47–50.
16. Herman JH, Khosia RC. Laser (Nd:YAG) induced healing of cartilage. *Arthritis Rheum* 1987;30[suppl]:S128.
17. Oyamada Y, Izu S. Application of low energy laser in chronic rheumatic arthritis and related rheumatoid diseases. Proceedings of the 6th Congress of the International Society of Laser Surgery and Medicine. San Diego: Wiley, 1985:80.
18. Caspers KH. Stimulation therapy with laser beams. *Phys Med Rehab* 1987;18:426.
19. Shiroto C, Ono K, Oshiro T. Laser stimulation therapy using a diode laser: 1,600 patients. *Lasers Surg Med* 1986;6:172.
20. Walker J. Relief from chronic pain by low power laser irradiation. *Neurosci Lett* 1983;43:339.
21. Walker J. Low level laser therapy for pain management: a review of the literature and underlying mechanisms. In: Oshiro T, Caldenhead RG, eds. *Low Level Laser Therapy: A Practical Introduction*. Chichester: John Wiley & Sons, 1988:42–56.
22. Shiroto C, Ono K, Oshiro T. Retrospective study of diode laser

- therapy for pain attenuation in 3635 patients: detailed analysis by questionnaire. *Laser Therapy* 1989;1:41-47.
23. Maeda T. Morphological demonstration of low reactive laser therapeutic pain attenuation effect of the GaAlAs laser. *Laser Ther* 1989;1:23-26.
 24. Moore K, Hira N, Kumar PS et al. A double-blind crossover trial of LLLT in the treatment of postherpetic neuralgia. *Laser Ther* 1989;1:7-10.
 25. Franquin JC. Biological effects of helium neon laser radiation. In: Hamdi M, ed. *Soft Laser 632: Clinical Use in Dental Medicine*. Geneva, Switzerland: Hamdi, 1993;11-15.
 26. Karu TI. Photobiological fundamentals of low-power laser therapy. *IEEE J Quant Electr* 1987;23:1703-1717.
 27. Olson JE, Schimmerling W, Tobias CA. Laser action spectrum of reduced excitability in nerve cells. *Brain Res* 1981;204:436-440.
 28. Rounds DE, Olson RS, Johnson E. The effect of the laser on cellular respiration. *Z Zellforsch* 1968;87:193.
 29. Salet C. A study of beating frequency of a single myocardial cell. I. Q-switched laser microirradiation of mitochondria. *Exp Cell Res* 1972;73:360-366.
 30. Salet C, Passarella S, Quagliariello E. Review article: effects of selective irradiation on mammalian mitochondria. *Photochem Photobiol* 1987;45:433-438.
 31. Salet C, Moreno G, Vinzens F. A study of beating frequency of a single myocardial cell. III. Laser microirradiation of mitochondria in the presence of KCN or ATP. *Exp Cell Res* 1979;120:25-29.
 32. Kitzes M, Twigg G, Berns MW. Alteration of membrane electrical activity in rat myocardial cells following selective laser microbeam irradiation. *J Cell Physiol* 1977;93:99-104.
 33. Passarella S, Casamassima E, Molinari S et al. Increase of proton electrochemical potential and ATP synthesis in rat liver mitochondria irradiated in vitro by HeNe laser. *FEBS Lett* 1984;175:95-99.
 34. Passarella S, Parlino E, Quagliariello E et al. Quantitative analysis of lymphocyte-salmonella interaction and effect of lymphocyte irradiation by helium-neon laser. *Biochem Biophys Res Commun* 1985;130:546-552.
 35. Passarella S, Roncalli L, Cicero R et al. New ultrastructural conformations of mitochondria irradiated in vitro with a helium-neon laser. *Laser Life Sci* 1988;2:161-171.
 36. Karu TI. Molecular mechanism of therapeutic effects of low intensity laser radiation. *Lasers Life Sci* 1988;2:53-74.
 37. Ciais G, Namer M, Schneider M et al. La lasertherapie dans la prevention et le traitement des mucosites liees a la chimiotherapie anticanceruse (Soft-laser therapy for prevention and treatment of mucositis induced cancer chemotherapy). *Bull Cancer* 1992;79:183-191.
 38. Pourreau-Schneider N, Soudry M, Franquin JC et al. Soft-laser therapy for iatrogenic mucositis in cancer patients receiving high-dose fluorouracil: a preliminary report. *J Natl Cancer Inst* 1992;84:358-359.
 39. Bensadoun RJ, Franquin JC, Ciais G et al. Low energy He-Ne laser in the prevention of radiation-induced mucositis. *Support Cancer Care* 1999;7:244-252.
 40. Cowen D, Tardieu C, Schubert M et al. Low energy He-Ne laser in the prevention of oral mucositis. *Int J Radiat Oncol Biol Phys* 1997;38:697-703.
 41. Barasch A, Peterson DE, Tanzer JM et al. He-Ne laser effects on conditioning-induced oral mucositis in bone marrow transplantation patients. *Cancer* 1995;76:2550-2556.
 42. Mahood DJ, Dose AM, Loprinzi CL et al. Inhibition of fluorouracil-induced stomatitis by oral cryotherapy. *J Clin Oncol* 1991;9:449-452.
 43. Pico JL, Avila-Garavito A, Naccache P. Mucositis: its occurrence, consequences, and treatment in the oncology setting. *Oncologist* 1998;3:446-451.
 44. Cascinu S, Fedeli A, Fedeli SL et al. Oral cooling (cryotherapy): an effective treatment for the prevention of 5-fluorouracil-induced stomatitis. *Eur J Cancer [B]* 1994;30:234-236.
 45. Labar B, Mrsic M, Pavletic Z et al. Prostaglandin E₂ for prophylaxis of oral mucositis following BMT. *Bone Marrow Transplant* 1993;11:379-382.
 46. Wadleigh RG, Redmen RS, Graham ML. Vitamin E in the treatment of chemotherapy-induced mucositis. *Am J Med* 1992;92:481-484.
 47. Miles EE. The modifying effects of beta-carotene on radiation and chemotherapy-induced oral mucositis. *Br J Cancer* 1988;57:416-417.
 48. Sonis ST, Lindquist L, Van Vugt A et al. Prevention of chemotherapy-induced ulcerative mucositis by transforming growth factor beta 3. *Cancer Res* 1994;54:1135-1138.
 49. Gordon B, Spadinger A, Hodges E et al. Effect of granulocyte-macrophage colony-stimulating factor on oral mucositis after hematopoietic stem-cell transplantation. *J Clin Oncol* 1994;12:1917-1922.
 50. Nemunaitis J, Rosenfeld CS, Ash R et al. Phase III randomized double blind placebo controlled trial of rh GM-CSF following allogeneic bone marrow transplant. *Bone Marrow Transplant* 1995;15:949-954.
 51. Rosso M, Blasi G, Gherlone E et al. Effect of granulocyte-macrophage colony-stimulating factor on prevention of mucositis in head and neck cancer patients treated with chemo-radiotherapy. *J Chemother* 1997;9:382-385.
 52. Kannan V, Bapsy PP, Anantha N et al. Efficacy and safety of granulocyte macrophage-colony stimulating factor (GM-CSF) on the frequency and severity of radiation mucositis in patients with head and neck carcinoma. *Int J Radiat Oncol Biol Phys* 1997;37:1005-1010.
 53. Karthus M, Rosenthal C, Paul H et al. Effect of topical oral GM-CSF application on oral mucositis in high-grade lymphoma patients treated with HD-methotrexate (HD-MRX): results of a randomized placebo-controlled trial. *Proc ASCO* 1998;17:61a.
 54. Serdar C, Heard R, Prathikanti R. Safety, pharmacokinetics and biologic activity of rHuKGF in normal volunteers: results of a placebo-controlled, randomized, double-blind, phase I study. *Blood* 1997;90:172a.
 55. Skubitz KM, Anderson PM. Oral glutamine to prevent chemotherapy induced stomatitis: a pilot study. *J Lab Clin Med* 1996;127:223-228.
 56. Anderson PM, Schroeder G, Skubitz KM. Oral glutamine reduces the duration and severity of stomatitis after cytotoxic cancer chemotherapy. *Cancer* 1998;83:1433-1439.
 57. Huang EY, Leung S, Wang CJ et al. Oral glutamine to alleviate radiation-induced oral mucositis: a pilot randomized trial. *Int J Radiat Oncol Biol Phys* 2000;46:535-539.
 58. Okuno SH, Foote RL, Loprinzi CL et al. A randomized trial of a nonabsorbable antibiotic lozenge given to alleviate radiation-induced mucositis. *Cancer* 1997;79:2193-2199.
 59. Symonds RP, McIlroy P, Khorrami J et al. The reduction of radiation mucositis by selective decontamination antibiotic pastilles: a placebo-controlled double-blind trial. *Br J Cancer* 1996;74:312-317.
 60. Leborgne JH, Leborgne F, Zubizarreta E et al. Corticosteroids and radiation mucositis in head and neck cancer: a double-blind placebo-controlled randomized trial. *Radiother Oncol* 1998;47:145-148.