

# UCLA

## UCLA Previously Published Works

### Title

Brain White Matter Abnormalities in Female Interstitial Cystitis/Bladder Pain Syndrome: A MAPP Network Neuroimaging Study

### Permalink

<https://escholarship.org/uc/item/66b5p2qf>

### Journal

Journal of Urology, 194(1)

### ISSN

0021-0005

### Authors

Farmer, Melissa A  
Huang, Lejian  
Martucci, Katherine  
et al.

### Publication Date

2015-07-01

### DOI

10.1016/j.juro.2015.02.082

Peer reviewed



Published in final edited form as:

*J Urol.* 2015 July ; 194(1): 118–126. doi:10.1016/j.juro.2015.02.082.

## Brain white matter abnormalities in female interstitial cystitis/ bladder pain syndrome: A MAPP Network neuroimaging study

Melissa A. Farmer<sup>1</sup>, Lejian Huang<sup>1</sup>, Katherine Martucci<sup>2</sup>, Claire C. Yang<sup>3</sup>, Kenneth R. Maravilla<sup>4</sup>, Richard E. Harris<sup>5</sup>, Daniel J. Clauw<sup>5</sup>, Sean Mackey<sup>2</sup>, Benjamin M. Ellingson<sup>6</sup>, Emeran A. Mayer<sup>6</sup>, Anthony J. Schaeffer<sup>7</sup>, and A. Vania Apkarian<sup>1,8,\*</sup> on behalf of the MAPP Research Network<sup>9</sup>

<sup>1</sup>Department of Physiology, Northwestern University, Feinberg School of Medicine, Chicago, IL

<sup>2</sup>Departments of Anesthesiology, Perioperative and Pain Medicine, Division of Pain Medicine, Stanford University Medical Center, Stanford, CA

<sup>3</sup>Departments of Urology, University of Washington, Seattle, WA

<sup>4</sup>Department of Radiology, University of Washington, Seattle, WA

<sup>5</sup>Department of Anesthesiology, and the Chronic Pain and Fatigue Research Center, University of Michigan, Ann Arbor, Michigan

<sup>6</sup>Gail and Gerald Oppenheimer Family Center for Neurobiology of Stress, David Geffen School of Medicine at UCLA, Los Angeles, CA

<sup>7</sup>Department of Urology, Northwestern University, Feinberg School of Medicine, Chicago, IL

<sup>8</sup>Departments of Surgery and Anesthesia, Northwestern University, Feinberg School of Medicine, Chicago, IL

### Abstract

**Purpose**—Several chronic pain conditions may be distinguished by condition-specific brain anatomical and functional abnormalities observed by imaging suggestive of underlying disease processes. Here we present the first characterization of IC/BPS-associated white matter (axonal) abnormalities based on multi-center neuroimaging from the Multidisciplinary Approach to the Study of Chronic Pelvic Pain (MAPP) Research Network.

**Materials and Methods**—Women with IC/BPS (n=34) and healthy controls (n=32) were assessed with questionnaires on pain, mood, and daily function. White matter microstructure was evaluated with diffusion tensor imaging (DTI) to model directional water flow along axons, or fractional anisotropy (FA). Regions that correlated with clinical parameters were further examined for sex and syndrome dependence.

**Results**—Women with IC/BPS exhibited numerous white matter abnormalities that correlated with severity of pain, urinary symptoms, and impaired quality of life. IC/BPS was characterized

\*Corresponding author: Dr. A. Vania Apkarian, Department of Physiology, Feinberg School of Medicine, Northwestern University, 300 E. Superior St., Tarry 7-705, Chicago, IL 60611, Tel.: (312) 503-0404, a-apkarian@northwestern.edu.

<sup>9</sup>Members of the MAPP Research Network members can be found in <sup>1</sup>

by decreased FA in aspects of the right anterior thalamic radiation, left forceps major, and right longitudinal fasciculus. Increased FA was detected in the right superior and bilateral inferior longitudinal fasciculi.

**Conclusions**—The first characterization of brain white matter abnormalities in women with IC/BPS reveals that regional decreases and increases in white matter integrity, across multiple axonal tracts, are associated with symptom severity in IC/BPS. Given that white matter abnormalities closely correlate with hallmark symptoms of IC/BPS, including bladder pain and urinary symptoms, brain anatomical alterations suggest neuropathological contributions to chronic urological pelvic pain.

### Keywords

diffusion tensor imaging; interstitial cystitis; bladder; pain; urgency; frequency

---

## INTRODUCTION

Interstitial cystitis/bladder pain syndrome (IC/BPS) is characterized by symptoms of persistent pelvic pain, urinary frequency, and urgency that are notoriously difficult to treat<sup>1,2</sup>. IC/BPS exacts a heavy toll on mood, sexual function, daily functioning, and quality of life<sup>3-5</sup>. IC/BPS continues to exact a heavy toll on mood, sexual function, daily functioning, and quality of life, despite numerous treatments directed towards peripheral pathology (e.g. inflammatory, infectious, muscular, and afferent abnormalities)<sup>6</sup>. Advances in the clinical conceptualization, diagnosis, and treatment of IC/BPS have been hampered by a paucity of biomarker evidence for peripheral and central mechanisms responsible for the initiation and maintenance of this syndrome.

Pain neuroimaging studies have demonstrated that clinical pain conditions exhibit unique changes in brain anatomy and function<sup>7</sup>. In healthy and disease states, brain anatomy and function are closely linked because neuronal activity is constrained by the structure and arrangement of neurons and axons that relay information<sup>8</sup>. White (axonal) matter facilitates the communication of neural information between and within brain regions, and abnormalities in these tracts can conceivably disrupt processing of sensory, motor, cognitive, and emotional information. Axonal structural integrity is inferred from the directions of water flow along the length of myelinated axons and is measured as fractional anisotropy (FA). The identification of anisotropic abnormalities in chronic prostatitis/chronic pelvic pain, irritable bowel syndrome, low back pain, and other pain conditions, strongly implies that axonal alterations play a mechanistic role in the development and/or maintenance of chronic pain<sup>9-12</sup>.

We report the first characterization of brain white matter anomalies in women with IC/BPS using non-invasive brain imaging technology as part of the multi-center Multidisciplinary Approach to the Study of Chronic Pelvic Pain (MAPP) Research Network. Diffusion tensor imaging (DTI) was used to evaluate water diffusion properties along axonal tracts in women with IC/BPS compared to healthy women. We hypothesized that a combination of regional increases and decreases in anisotropy in regions mediating sensorimotor, modulatory, and

cognitive processing would characterize IC/BPS and correlate with clinical symptoms of IC/BPS.

## MATERIALS AND METHODS

A convenience sample of participants from the MAPP Epidemiology/Phenotyping (EP) Study received DTI (n=201), gray matter anatomical (n=301), and resting state functional scans (n=297)<sup>1, 13</sup>. Here we report DTI data of female IC/BPS and gender/age-matched controls enrolled at Northwestern University (NU), University of California at Los Angeles (UCLA), and Stanford University (SU) between January 2011 and November 2013. All procedures were approved by the Institutional Review Boards of the respective sites, and participants provided written informed consent.

### Participants

Twenty-two women meeting criteria for IC/BPS were compared to age-matched ( $\pm 3$  years) healthy control women (n=32) (fig 1). Data from patients were excluded if they lacked age-matched controls (including 18 women with IC/BPS and 2 controls). IC/BPS patients who fulfilled MAPP inclusion/exclusion criteria (suppl. table 1) reported pelvic pain, pressure, or discomfort during the majority of the previous 3 months, with  $>1/10$  mean pelvic pain intensity (0 indicating no pain and 10 indicating worst imaginable pain).

### Experimental Design

Patients underwent DTI and T1-weighted scans in a single visit. Questionnaires administered included the Symptom and Health Care Utilization Questionnaire (SYM-Q), Hospital Anxiety and Depression Scale (HADS), McGill Pain Questionnaire-Short Form (SF-MPQ), Gracely Box Scales, Positive and Negative Affective Scales (PANAS), and the Genitourinary Pain Index (GUPI), including pain, urinary function, and quality of life subdomains.

### Imaging data acquisition

MRI scanning was performed at multiple sites using different scanner technology [3 Tesla (T) Siemens Trio (NU and UCLA), and 3T GE Discovery (SU)]. Neuroimaging data were collected, underwent quality control, and archived according to multi-site imaging procedures developed collaboratively between the MAPP Research Network, the UCLA PAIN repository and the UCLA Laboratory of Neuroimaging. Detailed procedures and description of the repository are available at [PAINrepository.org](http://PAINrepository.org) and acquisition parameters are described in the Supplementary Methods. All centers completed and passed center qualifications, including a set of pilot scans of a human volunteer.

## DATA ANALYSIS

DTI and T1-weighted images were obtained using the protocol described by Geha and colleagues<sup>14</sup> (see suppl. methods). Group contrasts of patient and control white matter yielded regions of interest (ROIs) that differed between groups ( $p < 0.001$ , corrected for multiple comparisons). Measures of white matter diffusivity (FA, axial diffusivity, radial diffusivity, and mean diffusivity) for each ROI were examined with planned post-hoc

Student's t-tests or Mann-Whitney U Rank Sums tests for non-normally distributed data. Clinical parameters were correlated with ROI anisotropy using Pearson correlations (Bonferroni corrected for multiple comparisons,  $p < 0.005$ ).

## RESULTS

### Participant Characteristics

The IC/BPS group (mean age=38.7) consisted of 95% Caucasian and 5% Hispanic patients reporting 11.4 years average pain duration and 4/10 average pain intensity (moderate clinical pain) on day of scanning. Total GUPI scores ranged from 1–38 (mean = 24.5, SE=2.2), with an average pain subscore of 11.4 (SE=1.05). GUPI-defined pain locations included the entrance to the vagina (41%), vagina (41%), urethra (59%), and below the waist in the pubic or bladder area (91%, refer to suppl. figure 1). Eight patients were taking medications, including oral narcotics (n=3), amitriptyline (n=4), cyclosporine (n=1), antimuscarinics (n=1), lyrica /neurontin/or tegretol (n=2), NSAIDs (n=1), valium (n=1) and a SSRI (n=1). Clinical parameters are summarized in Table 1 (refer to suppl. table 2 for detailed clinical profiles).

### Determination of center and age effects

Pooling imaging data from multiple centers can introduce variability due to technological differences and center recruitment biases. Indeed, mean FA values differed between centers ( $f_{2,148} = 13.91$ ,  $p < 0.001$ , fig 2B). To adjust for center effect, each subject's voxel-wise FA was corrected with the center's mean FA, and this value was added to the multi-center Grand mean FA (see suppl. methods section). Center-corrected FA values were negatively correlated with age, in agreement with previous studies (fig 2C). All subsequent analyses reflect center- and age-adjusted values.

### Whole brain contrast for white matter integrity differences

A whole-brain voxel-wise comparison using a common white matter skeleton was conducted to identify differences between IC/BPS and controls. Regional white matter reductions in patients (Control > Patient contrast) were observed in the (a) corticospinal tract in the left cerebellum, (b) anterior thalamic radiation in the right cerebellum, (c) right inferior fronto-occipital fasciculus in the right frontal orbital cortex, (d) right inferior longitudinal fasciculus in the lateral occipital cortex, (e) left forceps major adjacent to the precuneus, (f) right anterior thalamic radiation in the right frontal pole, (g) superior longitudinal fasciculus in the parietal cortex, and (h) temporal part of the left superior longitudinal fasciculus near the anterior cingulate cortex (ACC). In contrast, increased white matter FA in patients (Patient > Control contrast) was evident in the (a) inferior longitudinal fasciculus, (b) inferior fronto-occipital fasciculus bordering the right insula (INS), (c) forceps major near the left ACC, (d) superior longitudinal fasciculus in the right postcentral gyrus, as well as (e) left primary somatosensory cortex (S1), and (f) corticospinal tract passing through left S1.

## White matter properties of clinically-relevant regions

We hypothesized that abnormalities in white matter microstructure in IC/BPS would correlate with pain and urinary measures. FA (a general measure of white matter integrity) and diffusivity measures for specific directions were measured, including diffusion along the principle tract direction (axial diffusivity), diffusion perpendicular to the principle direction (radial diffusivity), and an average of diffusion in all directions (mean diffusivity). Additional planned post-hoc analyses were restricted to the originally identified ROIs (see above). Three areas of increased FA and three areas of decreased FA were correlated with syndrome-specific parameters (figs 3 and 4). Regional anisotropy in the left forceps major was significantly reduced in IC/BPS compared to controls ( $t_{1,52} = 2.63, p = 0.01$ , fig 3B), with a concurrent increase in radial diffusivity ( $t_{1,52} = -2.60, p = 0.012$ ). Similarly, regional FA in the right inferior longitudinal fasciculus was significantly decreased in patients ( $t_{1,52} = 3.17, p = 0.003$ ) and was accompanied by increased radial ( $t_{1,52} = -0.93, p = 0.005$ ) and mean ( $t_{1,52} = -2.17, p = 0.035$ ) diffusivity, as compared to controls. A region of the right anterior thalamic radiation showed significantly reduced FA in patients in relation to controls ( $t_{1,52} = 2.44, p = 0.02$ ), with no group differences in component diffusivity. Anisotropy values for these three regions negatively correlated with pain, urinary, and quality of life subscales of the GUPI (fig 3F, L, R), suggesting that these white matter properties reflect aspects of the IC/BPS clinical state.

Regional increases in anisotropy were also observed in segments of the left and right superior longitudinal fasciculus (in S1 and postcentral gyrus, respectively), left and right inferior longitudinal fasciculus (near the planum temporale and Heschl's gyrus, respectively), left forceps minor (adjacent to the ACC), right inferior fronto-occipital fasciculus (adjacent to INS), and the left corticospinal tract (in S1). FA in a portion of the right superior longitudinal fasciculus was significantly increased in IC/BPS ( $t_{1,52} = -4.69, p < 0.001$ ), with concurrent reductions in radial ( $t_{1,52} = 3.47, p = 0.001$ ) and mean ( $t_{1,52} = 2.46, p = 0.017$ ) diffusivity. Regional FA uniquely correlated with the pain ( $r = 0.36, p = 0.007$ ) and urinary ( $r = 0.44, p = 0.001$ ) subscales on the GUPI. In contrast, a portion of the left inferior longitudinal fasciculus exhibited significant increases in FA ( $t_{1,52} = 3.18, p = 0.002$ ) and axial diffusivity ( $t_{1,52} = 2.91, p = 0.005$ ). This region's FA was correlated with urinary symptom severity ( $r = 0.38, p = 0.007$ ), quality of life ( $r = 0.38, p = 0.005$ ) and anxiety ( $r = 0.38, p = 0.004$ ). Finally, FA in a segment of the right inferior longitudinal fasciculus was increased in patients ( $t_{1,52} = -3.60, p < 0.001$ ), which uniquely correlated with frequency of urinary severity ( $r = 0.38, p = 0.004$ ) and exhibited reduced radial diffusivity ( $t_{1,52} = 2.66, p = 0.01$ ). A summary of all findings is presented in table 2.

## DISCUSSION

Our findings reveal altered white matter microstructure across multiple axonal tracts in women with IC/BPS. Using diffusion-based neuroimaging, we identified both decreases and increases in regional white matter properties related to IC/BPS. Specifically, reduced anisotropy located in portions of the anterior thalamic radiation, forceps major, and inferior longitudinal fasciculus were associated with more severe pelvic pain, urinary symptoms, and poorer quality of life. Increased anisotropy in portions of the bilateral inferior longitudinal

fasciculus and superior longitudinal fasciculus correlated with pain severity and urinary dysfunction. Collectively, these microstructural abnormalities may influence the flow of neural information throughout the brain, thereby mediating brain reorganization previously observed in male pelvic pain<sup>10</sup>. This hypothesis is supported by IC/BPS-related shifts in oscillatory patterns of neuronal activity (function) and increased grey matter density (structure) in regions that modulate visceral and somatosensation and potentially pelvic floor motor function in women with IC/BPS<sup>15, 16</sup>. These anatomical abnormalities are strongly suggestive of neuropathological processes underlying IC/BPS.

Structural changes in axonal pathways can conceivably alter brain function in a disease-specific manner<sup>17</sup>. White matter abnormalities have been identified in multiple chronic pain conditions, including male pelvic pain, irritable bowel syndrome, low back pain, temporomandibular disorder, headache, fibromyalgia, and complex regional pain syndrome<sup>9–11, 18–21</sup>. Each condition has exhibited different patterns of altered microstructure, or white matter “signatures,” that may underlie distinct disease processes mediating the respective clinical symptoms. Despite these differences, IC/BPS also exhibits regional white matter abnormalities described in other pain conditions, including axonal projections to sensorimotor regions (e.g., thalamus, premotor area, S1), modulatory hubs serving diverse cognitive, emotional, and autonomic functions (e.g., ACC, INS), and frontal cortical regions modulating executive function and self-awareness (e.g., frontal pole)<sup>7, 14, 18, 19, 22, 20, 21</sup>. Furthermore, robust correlations between anisotropy and symptom severity strongly suggest that neuroanatomical changes may mediate clinical manifestations of IC/BPS that have, until now, been treated as purely peripheral phenomena.

The neurological significance of abnormal white matter properties in IC/BPS may implicate changes in axonal integrity (e.g., number/density of membranes), degree of myelination, fiber organization, and/or axonal branching. Reduced anisotropy is a common (and thus nonspecific) correlate of neurodegenerative disease progression, including loss of cognitive and motor function<sup>23</sup>. Regions with reduced anisotropy that correlated with IC/BPS symptom severity often exhibited increased radial diffusivity, which is suggestive of reduced axonal membrane density, axonal branching, and/or fiber crossing. Interestingly, increased anisotropy is a more unusual finding in clinical populations. Elevated anisotropy and axial diffusivity in frontal and sensorimotor regions may be partially explained by the hypothesis that elevated corticospinal anisotropy is the result of new motor learning, as this process requires the formation of newly myelinated axons needed to enhance anisotropy<sup>24</sup>. As a result, distinct white matter properties are closely linked with symptom severity and potentially new motor learning of postural changes or pelvic floor muscle control related to pain.

It remains unclear whether these white matter properties are causes or consequences of IC/BPS. White matter architecture may reflect a predisposition to develop disease, given evidence that regional anisotropy predicts future transition to Alzheimer’s disease and chronic back pain<sup>11, 25</sup> and may even render a healthy individual vulnerable to develop posttraumatic stress disorder after a traumatic stressor<sup>26</sup>. Alternately, white matter properties distinguished in neurological and psychiatric populations suggest that anisotropy is a consequence of disease progression. For instance, symptom-correlated reductions in



regional anisotropy with concurrent increased radial diffusivity are observed with epilepsy<sup>27</sup>, traumatic brain injury<sup>28</sup>, amyotrophic lateral sclerosis<sup>23</sup>, Alzheimer's disease<sup>29</sup>, and schizophrenia<sup>30</sup>. Although neurodegenerative changes are more subtle in chronic pain than in other neurological diseases, these populations consistently show correlations between symptom severity and pathological reductions in anisotropy. In particular, the association between pain with bladder filling and increased brain functional connectivity in women with IC/BPS may reflect altered brain function mediated by anisotropy changes<sup>16</sup>. We speculate that this combination of white matter abnormalities may reflect both the predisposition to develop IC/BPS pain—particularly in regions of decreased anisotropy<sup>11</sup>—as well as consequences of IC/BPS disease progression—in regions of increased anisotropy. Although future longitudinal studies are required to test this hypothesis, the present study has taken the first step in this direction by establishing evidence of neuropathological involvement in IC/BPS.

### Potential Clinical Implications

The identification of measurable neuropathological changes underlying IC/BPS advances the ongoing efforts to stratify urological pain patients into mechanistically- distinct subgroups. Such clinical phenotyping requires extremely large sample sizes only attainable through research collaborations like MAPP; yet even data from a limited cross-sectional patient sample reveals that patient-reported symptoms used in IC/BPS diagnosis can tap into biologically-relevant processes that shape axonal microstructure. The second phase of MAPP will use longitudinal neuroimaging to help clarify whether these abnormalities reflect predispositions or consequences of IC/BPS in order to facilitate early detection of vulnerable patient populations requiring early interventions. Conversely, if altered anisotropy is a consequence of IC/BPS, novel therapies that target pain-related neuroplasticity can be added to the treatment arsenal.

### CONCLUSION

Novel findings of regional increases and decreases in white matter anisotropy in with women IC/BPS, compared to controls without this syndrome, are associated with pain severity, urological symptoms, and quality of life. These regional changes are found in axonal tracts that traffic information between lobes and hemispheres and may potentially alter the function of communication pathways that transmit sensory, cognitive, and emotional information. IC/BPS white matter abnormalities are therefore candidate markers for neuropathological features of IC/BPS.

### Supplementary Material

Refer to Web version on PubMed Central for supplementary material.

### Acknowledgments

Funding for the MAPP Research Network was obtained under a cooperative agreement from National Institute of Diabetes and Digestive and Kidney Diseases (NIDDK), National Institutes of Health (NIH) (DK82370, DK82342, DK82315, DK82344, DK82325, DK82345, DK82333, and DK82316.).



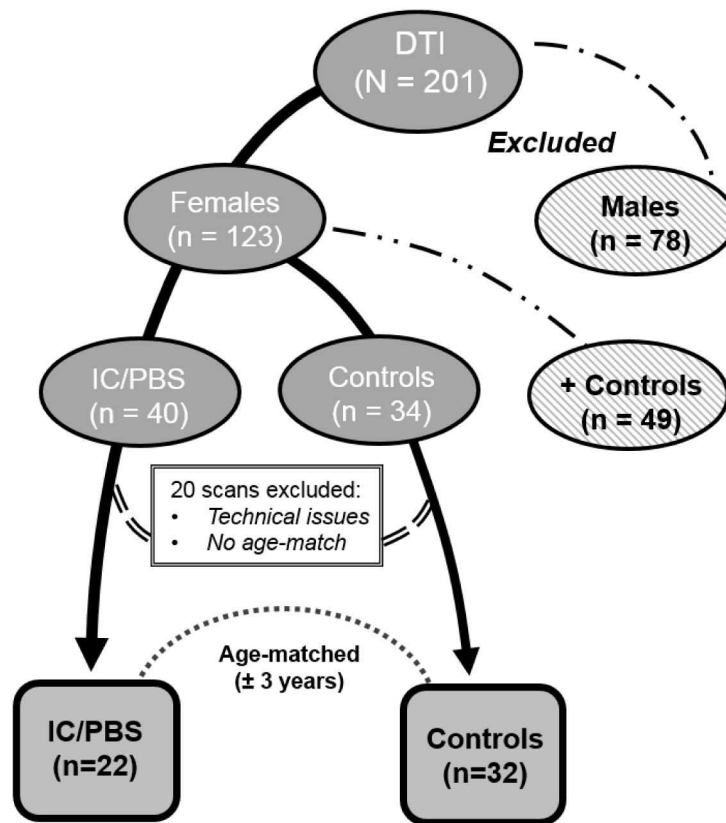
## Abbreviations and acronyms

<b>ACC</b>	anterior cingulate cortex
<b>AD</b>	axial diffusivity
<b>FA</b>	fractional anisotropy
<b>DTI</b>	diffusion tensor imaging
<b>IC/BPS</b>	interstitial cystitis/bladder pain syndrome
<b>INS</b>	insula
<b>MAPP</b>	Multidisciplinary Approach to the Study of Chronic Pelvic Pain
<b>MD</b>	mean diffusivity
<b>MRI</b>	magnetic resonance imaging
<b>NU</b>	Northwestern University
<b>RD</b>	radial diffusivity
<b>ROI</b>	region of interest
<b>S1</b>	primary somatosensory cortex
<b>SU</b>	Stanford University
<b>UCLA</b>	University of California at Los Angeles

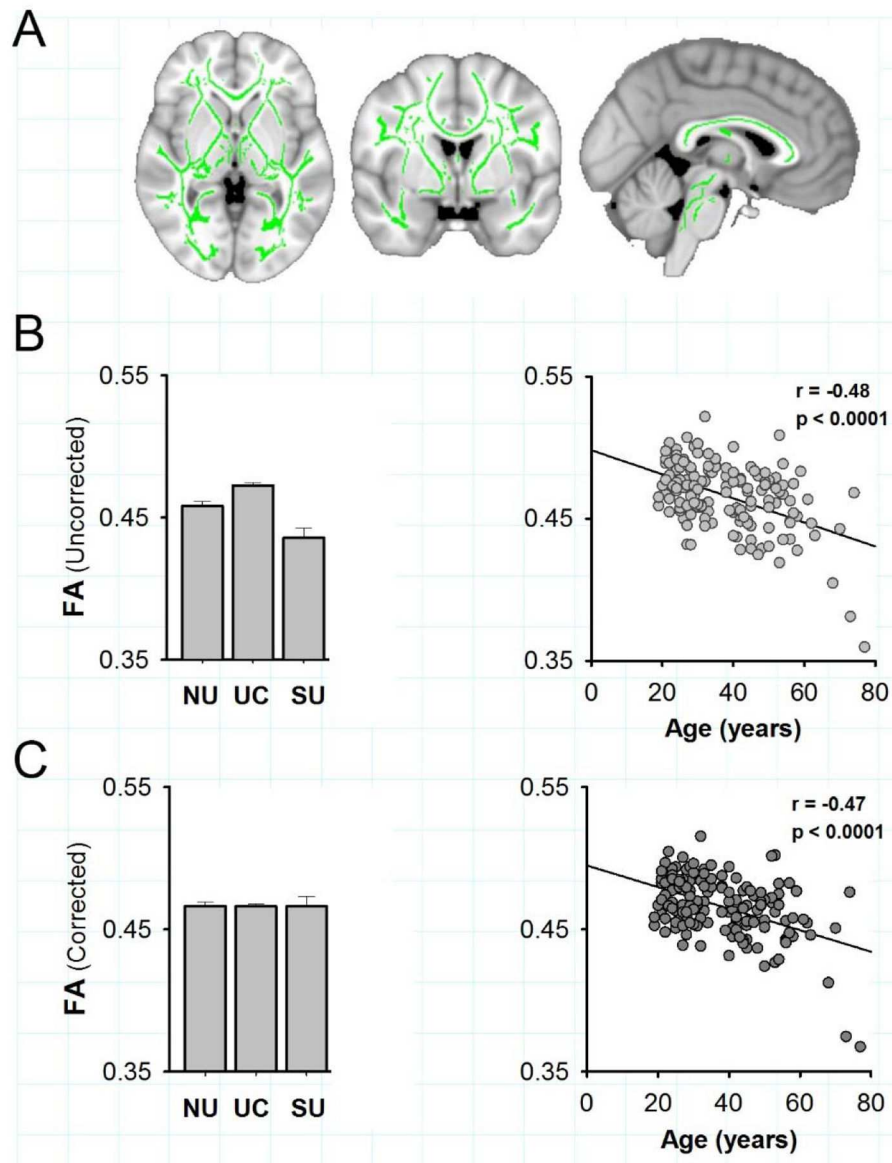
## References

1. Clemens JQ, Mullins C, Kusek JW, et al. The MAPP research network: a novel study of urologic chronic pelvic pain syndromes. *BMC Urol.* 2014; 14:57. [PubMed: 25085007]
2. Konkle KS, Berry SH, Elliott MN, et al. Comparison of an interstitial cystitis/bladder pain syndrome clinical cohort with symptomatic community women from the RAND Interstitial Cystitis Epidemiology study. *J Urol.* 2012; 187:508. [PubMed: 22177158]
3. Forrest JB. Epidemiology and quality of life. *J Reprod Med.* 2006; 51:227. [PubMed: 16676917]
4. Katz L, Tripp DA, Nickel JC, et al. Disability in women suffering from interstitial cystitis/bladder pain syndrome. *BJU Int.* 2013; 111:114. [PubMed: 22578191]
5. Nickel JC, Tripp DA, Pontari M, et al. Interstitial cystitis/painful bladder syndrome and associated medical conditions with an emphasis on irritable bowel syndrome, fibromyalgia and chronic fatigue syndrome. *J Urol.* 2010; 184:1358. [PubMed: 20719340]
6. Giannantoni A, Bini V, Dmochowski R, et al. Contemporary management of the painful bladder: a systematic review. *Eur Urol.* 2012; 61:29. [PubMed: 21920661]
7. Apkarian AV, Hashmi JA, Baliki MN. Pain and the brain: Specificity and plasticity of the brain in clinical chronic pain. *Pain.* 2011; 152:s49. [PubMed: 21146929]
8. Honey CJ, Thivierge JP, Sporns O. Can structure predict function in the human brain? *Neuroimage.* 2010; 52:766. [PubMed: 20116438]
9. Chen JY, Blankstein U, Diamant NE, et al. White matter abnormalities in irritable bowel syndrome and relation to individual factors. *Brain Res.* 2011; 1392:121. [PubMed: 21466788]
10. Farmer MA, Chanda ML, Parks EL, et al. Brain functional and anatomical changes in chronic prostatitis/chronic pelvic pain syndrome. *J Urol.* 2011; 186:117. [PubMed: 21571326]
11. Mansour AR, Baliki MN, Huang L, et al. Brain white matter structural properties predict transition to chronic pain. *Pain.* 2013; 154:2160. [PubMed: 24040975]

12. Rayhan RU, Stevens BW, Timbol CR, et al. Increased brain white matter axial diffusivity associated with fatigue, pain and hyperalgesia in Gulf War illness. *PLoS One*. 2013; 8:e58493. [PubMed: 23526988]
13. Landis JR, Williams DA, Lucia MS, et al. The MAPP research network: design, patient characterization and operations. *BMC Urol*. 2014; 14:58. [PubMed: 25085119]
14. Geha PY, Baliki MN, Harden RN, et al. The brain in chronic CRPS pain: abnormal gray-white matter interactions in emotional and autonomic regions. *Neuron*. 2008; 60:570. [PubMed: 19038215]
15. Kairys AE, Schmidt-Wilcke T, Puiu T, et al. Increased Brain Gray Matter in the Primary Somatosensory Cortex is Associated with Increased Pain and Mood Disturbance in Interstitial Cystitis/Painful Bladder Syndrome Patients. *J Urol*. 2015; 193:131. [PubMed: 25132239]
16. Kilpatrick LA, Kutch JJ, Tillisch K, et al. Alterations in resting state oscillations and connectivity in sensory and motor networks in women with interstitial cystitis/painful bladder syndrome. *J Urol*. 2014; 192:947. [PubMed: 24681331]
17. Bick AS, Mayer A, Levin N. From research to clinical practice: implementation of functional magnetic imaging and white matter tractography in the clinical environment. *J Neurol Sci*. 2012; 312:158. [PubMed: 21864850]
18. Ellingson BM, Mayer E, Harris RJ, et al. Diffusion tensor imaging detects microstructural reorganization in the brain associated with chronic irritable bowel syndrome. *Pain*. 2013; 154:1528. [PubMed: 23721972]
19. Lutz J, Jager L, de Quervain D, et al. White and gray matter abnormalities in the brain of patients with fibromyalgia: a diffusion-tensor and volumetric imaging study. *Arthritis Rheum*. 2008; 58:3960. [PubMed: 19035484]
20. Moayed M, Weissman-Fogel I, Salomons TV, et al. White matter brain and trigeminal nerve abnormalities in temporomandibular disorder. *Pain*. 2012; 153:1467. [PubMed: 22647428]
21. Teepker M, Menzler K, Belke M, et al. Diffusion tensor imaging in episodic cluster headache. *Headache*. 2012; 52:274. [PubMed: 22082475]
22. Moayed M, Weissman-Fogel I, Crawley AP, et al. Contribution of chronic pain and neuroticism to abnormal forebrain gray matter in patients with temporomandibular disorder. *Neuroimage*. 2011; 55:277. [PubMed: 21156210]
23. Catani M. Diffusion tensor magnetic resonance imaging tractography in cognitive disorders. *Curr Opin Neurol*. 2006; 19:599. [PubMed: 17102700]
24. McKenzie IA, Ohayon D, Li H, et al. Motor skill learning requires active central myelination. *Science*. 2014; 346:318. [PubMed: 25324381]
25. Fu JL, Liu Y, Li YM, et al. Use of diffusion tensor imaging for evaluating changes in the microstructural integrity of white matter over 3 years in patients with amnesic-type mild cognitive impairment converting to Alzheimer's disease. *J Neuroimaging*. 2014; 24:343. [PubMed: 24251793]
26. Sekiguchi A, Sugiura M, Taki Y, et al. Brain structural changes as vulnerability factors and acquired signs of post-earthquake stress. *Mol Psychiatry*. 2013; 18:618. [PubMed: 22614289]
27. Evstigneev VV, Kistsen VV, Bulaev IV, et al. The effect of structural white matter abnormalities on the clinical course of epilepsy. *Adv Clin Exp Med*. 2013; 22:529. [PubMed: 23986213]
28. Shenton ME, Hamoda HM, Schneiderman JS, et al. A review of magnetic resonance imaging and diffusion tensor imaging findings in mild traumatic brain injury. *Brain Imaging Behav*. 2012; 6:137. [PubMed: 22438191]
29. Amlie IK, Fjell AM. Diffusion tensor imaging of white matter degeneration in Alzheimer's disease and mild cognitive impairment. *Neuroscience*. 2014; 276:206. [PubMed: 24583036]
30. Fitzsimmons J, Kubicki M, Shenton ME. Review of functional and anatomical brain connectivity findings in schizophrenia. *Curr Opin Psychiatry*. 2013; 26:172. [PubMed: 23324948]

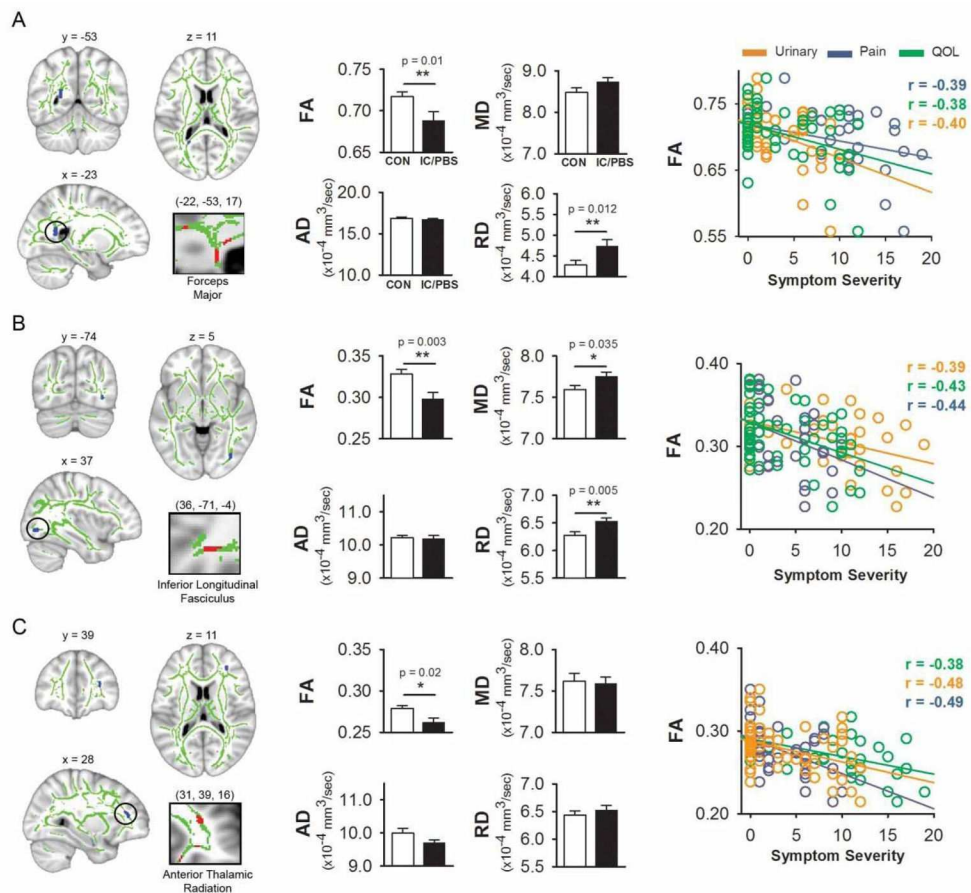


**Figure 1. Flow diagram for MAPP participants with diffusion tensor imaging data**  
Diffusion tensor imaging (DTI) data in MAPP patients and controls who had underwent in-depth epidemiological phenotyping.



**Figure 2. Center and age corrections for multi-center white matter properties**

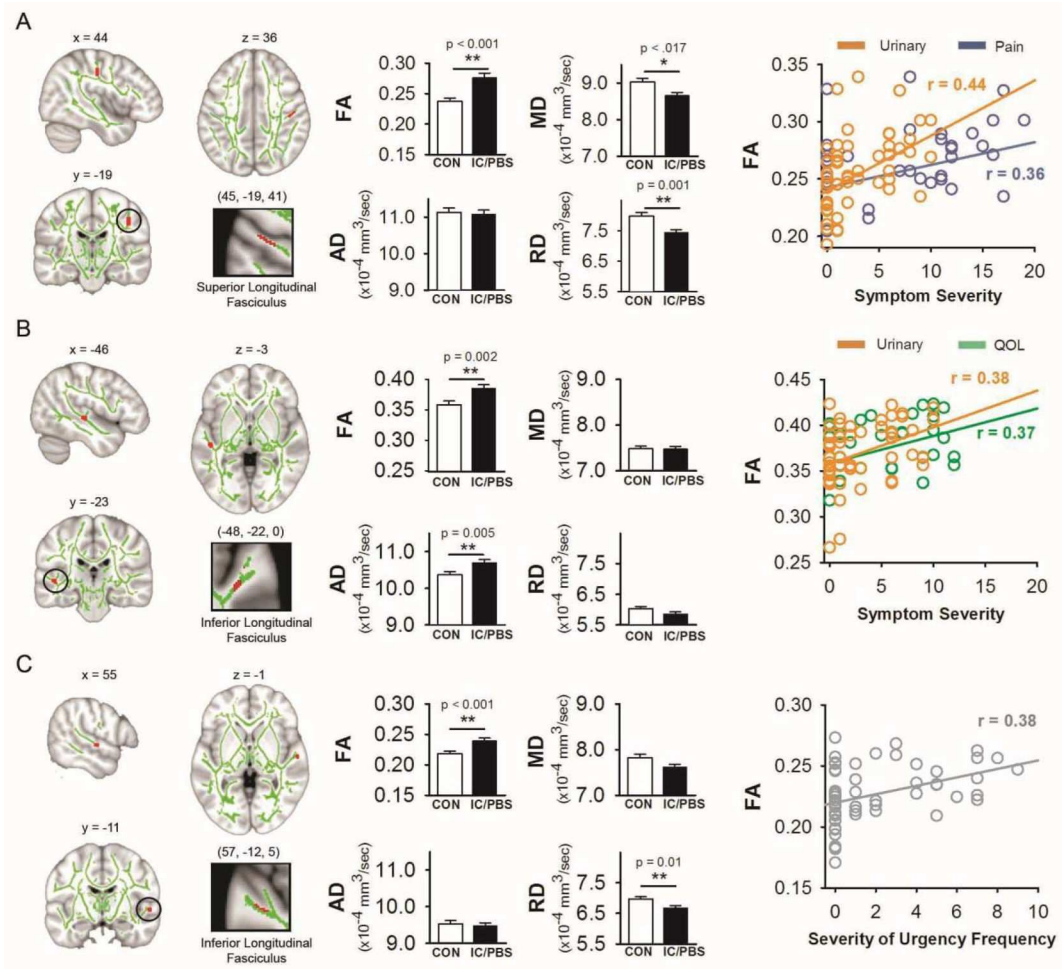
All Trans-MAPP DTI data (including male and female UCPPS, positive controls, and healthy controls) were examined to determine potential biases in data across centers. **A)** Brain slices showing the mean FA map (or "skeleton," in green) of pooled patients and controls represents white matter regions that common to all participants. **B)** Bar graph depicts the significant center differences in mean FA ( $\pm$  S.E.) (left panel), and pooled mean FA values were negatively correlated with age (scatter plot). **C)** Following statistical corrections for center (see suppl. methods), no center differences in mean FA remain, and corrected mean FA values are still negatively correlated with age (scatter plot).



**Figure 3. IC/BPS patients exhibited regional decreases in anisotropy that correlated with severity of clinical symptoms**

White matter anisotropy (FA) was examined with changes in diffusivity, including mean diffusivity (water diffusion in all directions), axial diffusivity (water diffusion along the principal axon fiber direction), and radial diffusivity (diffusion perpendicular to the principal axon fiber direction). **A**) A region in left forceps major (left panel) showed reduced FA compared to controls, with no changes in mean or axial diffusivity and increased radial diffusivity (middle panel). **B**) A region in right inferior longitudinal fasciculus (left panel) exhibited reduced FA compared to controls, with no changes in axial diffusivity and increased mean and radial diffusivity (middle panel). **C**) A region in right anterior thalamic radiation (left panel) showed reduced FA compared to controls, with no changes in mean, axial, or radial diffusivity (middle panel). For all three regions, was negatively correlated with pelvic pain, poorer quality of life, and urinary symptoms (**A–C**, right panels).

Note: \*  $p \leq 0.01$ , \*\*  $p \leq 0.001$



**Figure 4. IC/BPS patients exhibited regional increases in anisotropy that correlated with severity of clinical symptoms**

White matter anisotropy was examined with changes in diffusivity, including mean, axial, and radial diffusivity. **A)** A region in right superior longitudinal fasciculus (left panel) showed increased FA compared to controls, with no changes in axial diffusivity and reduced mean and radial diffusivity (middle panel). Regional FA correlated with urinary symptoms, and pelvic pain to a lesser extent (right panel). **B)** A region in left inferior longitudinal fasciculus (left panel) exhibited increased FA compared to controls, with no changes in mean or radial diffusivity and increased axial diffusivity (middle panel). Regional FA correlated with both urinary symptoms and poorer quality of life (right panel). **C)** Another region in the inferior longitudinal fasciculus (left panel) showed increased FA compared to controls, with no changes in mean or axial diffusivity and decreased radial diffusivity (middle panel). Regional FA correlated with a severity measure of frequent reports of urinary urgency (right panel). *Note:* \*  $p \leq 0.01$ , \*\*  $p \leq 0.001$



**Table 1**

Clinical and pain parameters in women with IC/BPS and healthy controls

Clinical parameters	IC/BPS	Controls	T value	Alpha
	Mean (SD)	Mean (SD)		
Age	38.73 (12.98)	32.84 (10.29)	1.86	0.07
Sleep	0.14 (6.27)	10.63 (4.92)	7.06	< 0.001**
Mood				
Anxiety	8.18 (3.16)	3.19 (3.87)	5.01	< 0.001**
Depression	5.00 (2.91)	2.09 (2.02)	4.36	< 0.001**
Negative emotion	18.27 (5.28)	12.00 (4.17)	4.88	< 0.001**
Positive emotion	28.73 (8.04)	35.31 (9.86)	2.59	0.012*

Author Manuscript

Author Manuscript

Author Manuscript

Author Manuscript



**Table 2**

Pain parameters on scan day in 22 women with IC/BPS

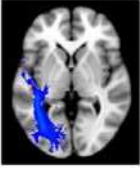
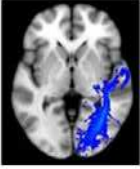
Intensity (0–20)	8.14 ± (4.88)
Unpleasantness (0–20)	7.36 ± (4.30)
Duration (yrs)	11.36 ± (12.65)
MPQ - Total	9.77 ± (6.71)
Sensory domain	7.09 ± (4.96)
Affective domain	2.27 ± (3.10)
GUPI - Total	24.50 ± (10.41)
GUPI pain	11.36 ± (4.94)
GUPI urinary	5.77 ± (2.74)
GUPI Quality of life	7.36 ± (3.60)

*Note.* Clinical measures collected on the day of scanning. Sleep assessed with Patient-Reported Outcomes Measurement Information System (PROMIS) Sleep Disturbance items; anxiety and depression scores from Hamilton Anxiety and Depression Scale (HADS); degree of positive and negative emotions from Positive and Negative Affective Scale (PANAS); pain intensity and unpleasantness from Gracely Pain Scale; McGill Pain Questionnaire (MPQ) total score and sensory/affective subscales; Genitourinary Pain Index (GUPI).

**Table 3**

Summary of white matter abnormalities and clinical correlates in women with IC/BPS

Tract Name	Regions Connected by Tracts	FA	AD	RD	MD	Structural Implications	Clinical correlates with FA	
<b>Regions showing decreased white matter integrity</b>								
	L forceps major	bilateral occipital lobes	↓↓		↑↑	↓ axonal integrity/ Demyelination ↑ axonal branching	<ul style="list-style-type: none"> <li>• Pelvic pain</li> <li>• Urinary dysfunction</li> <li>• Quality of life</li> </ul>	
	R inferior longitudinal fasciculus	temporal and occipital lobes	↓↓		↑↑	↑↑	↓ axonal integrity/ Demyelination ↑ axonal branching	<ul style="list-style-type: none"> <li>• Pelvic pain</li> <li>• Urinary dysfunction</li> <li>• Quality of life</li> </ul>
	R anterior thalamic radiation	anterior & dorsomedial thalamic nuclei with frontal cortex	↓↓				↓ axonal integrity/ demyelination	<ul style="list-style-type: none"> <li>• Pelvic Pain</li> <li>• Urinary dysfunction</li> <li>• Quality of life</li> </ul>
<b>Regions showing increased white matter integrity</b>								
	R superior longitudinal fasciculus	bi-directional fibers linking frontal, occipital, parietal, and temporal lobes	↑↑		↓↓	↓↓	↑ axonal integrity/ myelination ↓ axonal branching	<ul style="list-style-type: none"> <li>• Pelvic pain</li> <li>• Urinary dysfunction</li> </ul>

	Tract Name	Regions Connected by Tracts	FA	AD	RD	MD	Structural Implications	Clinical correlates with FA
	L inferior longitudinal fasciculus	temporal and occipital lobes	↑↑	↑↑			↑ axonal integrity/ myelination	<ul style="list-style-type: none"> <li>• Urinary dysfunction</li> <li>• Quality of life</li> </ul>
	R inferior longitudinal fasciculus	temporal and occipital lobes	↑↑		↓↓		↑ axonal integrity/ myelination ↓ axonal branching	<ul style="list-style-type: none"> <li>• Pelvic pain</li> <li>• Urinary frequency</li> </ul>

Author Manuscript

Author Manuscript

Author Manuscript

Author Manuscript