

UC San Diego

UC San Diego Previously Published Works

Title

Fetal Alcohol Syndrome: A Case Report of Neuropsychological, MRI, and EEG Assessment of Two Children

Permalink

<https://escholarship.org/uc/item/6cq7229t>

Journal

Alcoholism Clinical and Experimental Research, 16(5)

ISSN

0145-6008

Authors

Mattson, Sarah N
Riley, Edward P
Jernigan, Terry L
[et al.](#)

Publication Date

1992-10-01

DOI

10.1111/j.1530-0277.1992.tb01909.x

Peer reviewed

RAPID COMMUNICATION

Fetal Alcohol Syndrome: A Case Report of Neuropsychological, MRI, and EEG Assessment of Two Children

Sarah N. Mattson, Edward P. Riley, Terry L. Jernigan, Cindy L. Ehlers, Dean C. Delis, Kenneth L. Jones, Catherine Stern, Kathleen A. Johnson, John R. Hesselink, and Ursula Bellugi

Neuropsychological, neuroanatomical, and electrophysiological data are presented on two subjects with fetal alcohol syndrome (FAS). Both boys had intelligence quotients in the mentally deficient range and were found to have several other severe, specific deficits. Magnetic resonance imaging showed abnormalities of the corpus callosum, and reductions in the size of the basal ganglia and thalamic structures. No focal abnormalities were noted in the electroencephalogram records, although the electroencephalograms of both boys were moderately abnormal for their age group. A multidisciplinary approach to the study of FAS, hopefully will lead to a more unified concept of the disorder and perhaps indicate specific areas of vulnerability.

Key Words: Fetal Alcohol Syndrome, Neuropsychological Assessment, Magnetic Resonance Imaging, Electroencephalogram.

FETAL ALCOHOL SYNDROME (FAS) is associated with a variety of central nervous system (CNS) anomalies.^{1,2} Behaviorally, these children are typically retarded and may show attentional deficits. Morphologically, numerous abnormalities (e.g., agenesis of the corpus callosum, migration errors) have been reported, but these reports have relied primarily on postmortem examination in infants.³ This sample, therefore, may not be representative of the larger population with FAS. Similarly, previous electroencephalogram (EEG) studies have focused primarily on infants,⁴⁻⁶ and little electrophysiological data exists on older children with FAS. However, the data

indicate that EEG may be very sensitive to an alcohol insult.

This report documents two cases of FAS using a multidisciplinary approach, including: a neuropsychological examination, magnetic resonance imaging (MRI), and electrophysiological (EEG) testing. The neuropsychological exam provides information concerning affected brain areas and an assessment of current functioning, including strengths and weaknesses. MRI provides three-dimensional morphological information about the brain and a quantitative assessment of which areas of the brain are affected. Lastly, EEG should theoretically provide one functional link between the anatomical anomalies and behavioral dysfunctions observed in children exposed to alcohol prenatally.

SUBJECTS

Both subjects described here are part of a larger project in San Diego. The caregiver of each child was initially contacted by Dr. K. L. Jones and asked to participate in the study. Subject 1 is a 13-year-old white male and subject 2, a 14-year-old black male. Both had previously been diagnosed as having FAS by Dr. Jones and both were taking medication at the time of testing (subject 1: phenobarbital, thioridazine, and flurazepam; subject 2: pemoline).

NEUROPSYCHOLOGICAL TESTING

Each child was administered a battery of neuropsychological tests. The tests given⁷⁻¹⁴ and the results obtained are outlined in Table 1. Both children's intelligence quotients (IQs) were in the mentally deficient range and both demonstrated severe deficits in immediate memory span for words, word comprehension, verbal fluency, naming, visual-motor integration, and memory for motor sequences. Additionally, they both showed mild to moderate difficulty with immediate memory span for digits, abstract thinking, and immediate memory for a story.

Performances on the California Verbal Learning Test-Children's version¹⁴ (CVLT-C) were compared with two groups of children, one matched for chronological age,

From the SDSU/UCSD Joint Doctoral Program in Clinical Psychology (S.N.M., E.P.R., C.S.), San Diego VA Medical Center (T.L.J., D.C.D.), UCSD School of Medicine (T.L.J. D.C.D., K.L.J., K.A.J., J.R.H.), Research Institute of Scripps Clinic (C.L.E.), and Cognitive Neurosciences Laboratory, The Salk Institute for Biological Studies (U.B.), San Diego, California.

Received for publication February 26, 1992; accepted May 18, 1992

This research was supported in part by National Institute on Alcohol Abuse and Alcoholism grant numbers AA06902 and AA03249 to EPR, National Institute of Neurological Disorders and Stroke, grant number NS22343 for the Center for the Study of the Neurological Basis of Language, National Institute of Child Health and Human Development grant number HD26022 to UB, and General Clinical Research Center grant number RR00833 to Scripps Clinic.

Reprint requests: Dr. E. P. Riley, Department of Psychology, San Diego State University, San Diego, CA 92182-0350.

Copyright © 1992 by The Research Society on Alcoholism.

Table 1. Results of the Neuropsychological Testing for Subjects 1 and 2

Test	Subject 1	Subject 2
WISC-R*		
Full Scale IQ	51 (<1%)	41 (<1%)
Verbal Scale IQ	45 (<1%)	46 (<1%)
Performance Scale IQ	67 (1%)	46 (<1%)
Subtests:		
Information	1 (1%)	1 (1%)
Similarities	1 (1%)	1 (1%)
Arithmetic	2 (1%)	1 (1%)
Vocabulary	1 (1%)	1 (1%)
Comprehension	1 (1%)	3 (1%)
Digit span	1 (1%)	1 (1%)
Picture completion	7 (16%)	3 (1%)
Picture arrangement	1 (1%)	1 (1%)
Block design	6 (9%)	1 (1%)
Object assembly	9 (37%)	4 (2%)
Coding	1 (1%)	1 (1%)
Mazes	5 (5%)	1 (1%)
McCarthy Scales†, ¶		
Verbal Memory I (words)	-5§	-3
Verbal Memory II (story)	-1	-1
Opposite analogies	-2	-1
Numerical memory-forward	-2	-2
Numerical memory-backward	-2	-2
PPVT-R‡		
Verbal fluency‡	<10%	<10%
Boston Naming Test†, ¶	-5§ (20/60)	-5§ (31/60)
Finger tapping†	R:-2; L:0	R:-1; L:-1
Visual-motor integration‡	1%	<1%
K-ABC hand movements‡	2%	<1%
CVLT-C†		
List A total recall	-4	-5§
Short delay free recall	-2	-5§
Long delay free recall	-3	-5§
Perseverations	+3	+3
Total intrusions	+5§	+5§
Recognition discriminability	-5§	-5§
False positives (recognition)	+5§	+5§

* WISC-R IQ scores are expressed as standard scores, with mean = 100, SD = 15; subtest scores are expressed as scaled scores, with mean = 10, SD = 3.

† McCarthy, BNT, finger tapping, and CVLT-C scores are expressed as relative standings, in standard deviations, i.e., a score of 0 is average.

‡ PPVT-R, Verbal fluency, VMI, and K-ABC scores are expressed as percentiles.

§ Standard scores are capped at ±5 SD.

¶ McCarthy and BNT scores are compared with norms for 12-year-old males.

and one matched for mental age (according to verbal IQ scores). When compared with children of similar chronological age, both subjects showed impaired immediate and delayed recall with excessive perseverations and intrusions. On recognition testing, they showed poor discrimination and an increase in false-positives. When compared with eight 5-year-old male controls, to equate mental age, both FAS subjects demonstrated relatively normal learning and recall. However, they still had excessive intrusions, and poor recognition discrimination with an increase in false-positive responses.

MAGNETIC RESONANCE IMAGING

A standard protocol was used for acquisition of MRI brain images.¹⁵ Briefly, two spin-echo pulse sequences were used to obtain images of the sagittal and axial planes. T1-weighted (repetition time = 600 msec; echo time = 20 msec) images were used for the sagittal views, while T2-weighted (repetition time = 2000 msec, echo time = 25 and 70 msec) images were used for the axial views.

Clinically, the MRI for subject 1 showed slightly asymmetrical but otherwise normal ventricles, normal sulci,

and no hyperintensities. The corpus callosum was moderately hypoplastic. For subject 2, the images showed normal sulci, complete agenesis of the corpus callosum, and enlargement of the atrial and temporal horns of the lateral ventricles. This ventricular enlargement is probably secondary to the agenesis of the corpus callosum.

Morphometric analyses were conducted on both subjects and comparisons were made with nine age-matched normal controls. These indicated that the cerebral and cerebellar cranial vaults were significantly reduced in the FAS cases relative to controls. In addition, within the cerebral cranial vault, there was an increased amount of ventricular or subarachnoid fluid, indicating volume loss of brain tissue. Gray matter reductions in the caudate and thalamus were disproportionate to the overall microcephaly while the volume of white matter was not reduced beyond that expected from the overall cerebral reduction. Since it is still possible that reduction in volume of these structures is due to the overall microcephaly, the FAS cases were compared with a group of age-matched children with Down's syndrome.¹⁶ The Down's syndrome children also show reductions in the volume of the cerebral cranial vault but the basal ganglia and thalamic structures are proportionally larger than expected for the amount of cerebral reduction.^{17,18} Fig. 1 summarizes the morphometric analyses.

ELECTROPHYSIOLOGY

Grass, gold-plated electrodes were placed, using the international 10-20 system, at F3, C3, P3, O1, T3, T5, F4, C4, P4, O2, T4, and T6. EEG was recorded on a Nihon-Kohden machine from both bipolar (parasagittal chains)

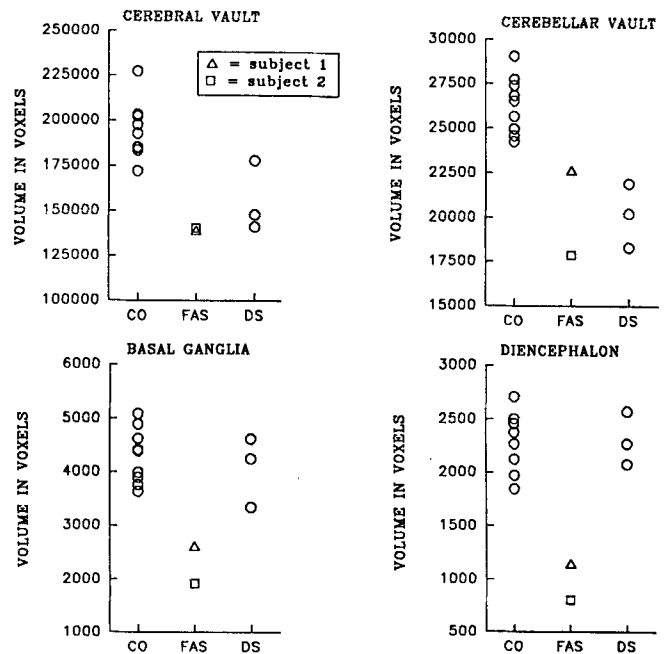


Fig. 1. The distributions of estimated volumes (in voxels) of the total supratentorial (cerebral) cranial vault, the total infratentorial (cerebellar) cranial vault, the combined caudate and lenticular nuclei (basal ganglia), and the combined thalamic, hypothalamic, and septal structures (diencephalon). Age-matched groups of nine normal controls (CO), two subjects with fetal alcohol syndrome (FAS) and three subjects with Down's syndrome (DS) are compared. For the FAS subjects, triangles represent subject 1 and squares represent subject 2.

and unipolar (referenced to the ipsilateral ear) montages. EEG was collected for a 5-min period from the awake subject with eyes closed.

Inspection of the paper records revealed that both EEGs were moderately abnormal. The dominant rhythm in both records was in the theta (4–6 Hz) range. In addition both records contained occasional delta (1–2 Hz) activity, predominantly in the posterior head regions. There was no focally abnormal EEG activity noted in either record and no asymmetries were found. Subject 1 had an excessive amount of fast activity in the 12 to 20 Hz range in all channels, but primarily in the frontal and central leads, probably due to medication. Alpha (8–12 Hz) activity was missing in this subject whereas in Subject 2, sparse 8 Hz activity was visible in the posterior leads.

DISCUSSION

This report provides preliminary information on three aspects of the effects of prenatal alcohol exposure in two severely affected children. Many of the results from the neuropsychological examination such as IQ are similar to those reported by others. However, because of the inclusion of additional tests, new insights about specific deficits can now be tested. For example, on the CVLT-C, besides difficulty in learning and recall, these two children had problems with recognition memory and gave a high number of false-positive responses. In contrast, children, aged 6 to 12, diagnosed with attention deficit hyperactivity disorder (ADHD), have a similar difficulty with learning and recall, but not with recognition or false-positive responses.¹⁹ This suggests that the deficits in learning and memory in children with FAS may lie at the encoding and storage level and are distinct from the attentional deficits commonly reported in relation to prenatal alcohol exposure.²⁰

In both cases, the MRI analysis showed abnormalities of the corpus callosum and reduced volumes of several brain structures. Importantly, the comparison between the children with Down's syndrome and the FAS cases indicates that the reduction in subcortical structures in children with FAS should not be considered as simply secondary to microcephaly. It is also important to note that anomalies of the corpus callosum have previously been reported in several cases of FAS. In a review of the neuropathology of FAS, Clarren³ reported three cases of callosal agenesis and an additional eight cases were reported in a review by Jeret et al.²¹ Given that the incidence of agenesis of the corpus callosum has been placed between 1 and 3 per 1000,²¹ Jeret concluded that callosal agenesis occurs sporadically in FAS. The EEGs revealed moderate abnormalities, with theta activity dominating the records in both subjects.

It must be stressed that these two cases represent the more severely affected end of the spectrum of FAS effects. However, it is possible that abnormalities observed using this multidisciplinary approach may help us to identify a

distinctive pattern of brain damage, both structural and functional, resulting from prenatal alcohol exposure. It may be possible to identify specific brain areas or behaviors that prove to be especially sensitive measures of the effects of alcohol. With the inclusion of more subjects and with subjects of different degrees of CNS involvement, perhaps a biological marker or "signature" of prenatal alcohol exposure can be found. This information might allow for early identification of fetal alcohol effects and thus for early intervention and appropriate remedial attention necessitated by prenatal alcohol exposure.

REFERENCES

1. Jones KL, Smith DW, Ulleland CN, Streissguth AP: Pattern of malformation in offspring of chronic alcoholic mothers. *Lancet* 1:1267–1271, 1973
2. Streissguth AP, Aase JM, Clarren SK, et al: Fetal alcohol syndrome in adolescents and adults. *JAMA* 265:1961–1967, 1991
3. Clarren SK: Neuropathology in fetal alcohol syndrome, in West JR (ed): *Alcohol and Brain Development*. New York, Oxford University Press, 1986, p 158
4. Chernick V, Childiaeva R, Ioffe S: Effects of maternal alcohol intake and smoking on neonatal electroencephalogram and anthropometric measurements. *Am J Obstet Gynecol* 1(146):41–47, 1983
5. Havlicek V, Childiaeva R: EEG Component of fetal alcohol syndrome. *Lancet* 2:477, 1976
6. Havlicek V, Childiaeva R, Chernick V: EEG Frequency spectrum characteristics of sleep states in infants of alcoholic mothers. *Neuropediatrics* 4:360–373, 1977
7. Wechsler D: *Manual for the Wechsler Intelligence Scale for Children-Revised*. San Antonio, The Psychological Corporation, 1974
8. McCarthy DA: *Manual for the McCarthy Scales of Children's Abilities*. San Antonio, The Psychological Corporation, 1972
9. Dunn LM, Dunn LM: *Peabody Picture Vocabulary Test-Revised*. Circle Pines, MN, American Guidance Service, 1981
10. Kaplan E, Goodglass H, Weintraub S: *Boston Naming Test*. Philadelphia, Lea & Febiger, 1983
11. Beery KE: *Manual for the Development Test of Visual-Motor Integration-3R*. Cleveland, Modern Curriculum Press, 1989
12. Kaufman AS, Kaufman NL: *K-ABC: Kaufman Assessment Battery for Children*. Circle Pines, MN, American Guidance Service, 1983
13. Boll T: *Children's Category Test*. San Antonio, The Psychological Corporation (in press)
14. Delis DC, Kramer JH, Kaplan E, Ober BA: *California Verbal Learning Test-Children's Version*. San Antonio, The Psychological Corporation (in press)
15. Jernigan TL, Bellugi U: Anomalous brain morphology on magnetic resonance images in Williams syndrome and Down syndrome. *Arch Neurol* 47:529–533, 1990
16. Bellugi U, Bihle A, Jernigan T, et al: Neuropsychological, neurological, and neuroanatomical profile of Williams syndrome. *Am J Med Genet* 6:115–125, 1990
17. Jernigan TL, Bellugi U, Sowell E, et al: Cerebral morphological distinctions between Williams and Down syndromes. *Arch Neurol* (in press)
18. Bellugi U, Wang P: Williams syndrome: An unusual neuropsychological profile, in Broman S, Graffman J (eds): *Atypical Cognitive Deficits in Developmental Disorders: Implications for Brain Function*. Hillsdale, Erlbaum Associates (in press)
19. Loge DV, Staton D, Beatty WW: Performance of children with ADHD on tests sensitive to frontal lobe dysfunction. *J Am Acad Child Adolesc Psychiatry* 29:540–545, 1990
20. Streissguth AP, Barr HM, Sampson PD, et al: Attention, distraction and reaction time at age 7 years and prenatal alcohol exposure. *Neurobehav Toxicol Teratol* 8:717–725, 1986
21. Jeret JS, Serur D, Wisniewski KE, Lubin RA: Clinicopathological findings associated with agenesis of the corpus callosum. *Brain Dev* 9:255–264, 1987