

UC Davis

UC Davis Previously Published Works

Title

Characterization of Degenerative Changes in the Temporomandibular Joint of the Bengal Tiger (*Panthera tigris tigris*) and Siberian Tiger (*Panthera tigris altaica*)

Permalink

<https://escholarship.org/uc/item/76r873hd>

Journal

Journal of Comparative Pathology, 149(4)

ISSN

0021-9975

Authors

Murphy, MK

Arzi, B

Vapniarsky-Arzi, N

et al.

Publication Date

2013-11-01

DOI

10.1016/j.jcpa.2013.05.003

Peer reviewed



DISEASE IN WILDLIFE OR EXOTIC SPECIES

Characterization of Degenerative Changes in the Temporomandibular Joint of the Bengal Tiger (*Panthera tigris tigris*) and Siberian Tiger (*Panthera tigris altaica*)

M. K. Murphy^{*}, B. Arzi^{*,†}, N. Vapniarsky-Arzi[‡] and K. A. Athanasiou^{*,§}

^{*} Department of Biomedical Engineering, [†] Department of Surgical and Radiological Sciences, School of Veterinary Medicine,

[‡] Department of Pathology, Microbiology and Immunology, William R. Pritchard Veterinary Medical Teaching Hospital and

[§] Department of Orthopaedic Surgery, University of California Davis, Davis, CA, USA

Summary

The articulation of the temporomandibular joint (TMJ) is composed of the temporal bone dorsally, the mandibular condyle ventrally and a fibrous articular disc. The TMJ disc plays an essential role in distributing load between the two articular surfaces. Degeneration of the disc in the presence of joint pathology has been shown in man; however, TMJ pathology has not been documented previously in tigers (*Panthera tigris*). The mandibular condyle and TMJ disc of a Bengal tiger (*P. tigris tigris*) and a Siberian tiger (*P. tigris altaica*) were evaluated grossly and the TMJ disc was characterized biochemically and mechanically. Characterization of the TMJ disc verified region- and direction-dependent biochemical and mechanical properties, reflective of the functional demands on the joint. Degenerative joint disease was observed in both cases and this was more severe in the Siberian tiger. Simultaneous evaluation of joint pathology, biochemical composition and mechanical properties of the TMJ disc revealed a loss in functional properties (tensile anisotropy) of the disc as joint pathology advanced from moderate to severe. TMJ degeneration may compromise the ability of the animal to eat and thrive and may be a factor contributing to the endangered status of these species.

© 2013 Elsevier Ltd. All rights reserved.

Keywords: arthritis; biomechanical properties; degenerative joint disease; histopathology

Introduction

The temporomandibular joint (TMJ) is a bilateral diarthrodial joint with an essential role in mastication, as well as in communication and survival. Its articulation is composed of the squamous temporal bone dorsally, the mandibular condyle ventrally and the articular disc, which divides the joint space into dorsal and ventral components. The anatomy of the joint is variable in mammals and is closely related to cranial morphology, masticatory patterns and dietary requirements (Nanci, 2003). As such, there is a close relationship between structure and function of the joint. This relationship is demonstrated by region-

and direction-dependent biochemical content and mechanical properties in the components of the joint (Detamore and Athanasiou, 2003; Allen and Athanasiou, 2006; Kalpakci *et al.*, 2011).

The structure of the TMJ disc is generally consistent across mammalian species and is closely related to the function of the disc. The disc is composed of fibrocartilaginous tissue that functions to distribute load between the dorsal and ventral bony joint components during joint motion. The disc is composed primarily of type I collagen with minimal glycosaminoglycan (GAG) content and low cellularity (Nakano and Scott, 1989; Detamore *et al.*, 2005; Scapino *et al.*, 2006). However, regional variability between species is related to the functional demands (Kalpakci *et al.*, 2011). Independent of species, collagen fibres

Correspondence to: K. A. Athanasiou (e-mail: athanasiou@ucdavis.edu).

0021-9975/\$ - see front matter

<http://dx.doi.org/10.1016/j.jcpa.2013.05.003>

© 2013 Elsevier Ltd. All rights reserved.

demonstrate rostrocaudal alignment in the central region of the disc and ring-like organization around the periphery of the disc (Detamore and Athanasiou, 2003; Scapino *et al.*, 2006; Arzi *et al.*, 2012). Mechanically, the disc demonstrates superior tensile properties in its central region, when tested rostrocaudally, compared with mediolaterally. The fibrocartilaginous disc of the TMJ plays a key role in distributing load throughout joint motion, which may be compromised in the presence of pathology.

The aetiology of TMJ pathology remains elusive; however, efforts have been made to characterize naturally occurring degenerative change in the TMJ of man and companion animals (Dworkin *et al.*, 1990). Up to 25% of the human population demonstrates symptoms of TMJ dysfunction (Solberg *et al.*, 1979). Notably, 70% of human patients with TMJ disorders demonstrate disc displacement and evidence of disc degeneration and over 50% demonstrate symptoms of osteoarthritis (Farrar and McCarty, 1979; Bertram *et al.*, 2001). Histologically, displaced discs have been shown to have abnormal collagen fibre arrangement, with fragmentation of fibrils, increased vasculature and cellular proliferation (Leonardi *et al.*, 2007). Disorders of the TMJ have recently been characterized in domestic dogs and cats via computed tomography (Arzi *et al.*, 2013). In that study, osteoarthritis was found to be the most common TMJ disorder in dogs and the second most common disorder in cats. Simultaneous characterization of the gross and histological properties of the disc, together with its biochemical content and organization and mechanical properties, may elucidate functional changes occurring with pathology of the TMJ. As TMJ pathology remains poorly understood, an effort to characterize degenerative changes in the tiger population may aid in conservation efforts towards the endangered status of the species.

The TMJ disc has not been characterized previously in an exclusively carnivorous mammal in health or disease. Additionally, TMJ pathology has not yet been characterized in the tiger. The present report describes degenerative TMJ disease in two ageing tigers (*Panthera tigris altaica* and *P. tigris tigris*).

Materials and Methods

Specimens

The TMJs were isolated from a 16-year-old neutered female Bengal tiger (*P. tigris tigris*) and a 17-year-old neutered male Siberian tiger (*P. tigris altaica*). Both tigers were humanely destroyed for reasons not related to TMJ arthritis. Each TMJ disc was dissected from the condylar process and temporal bone. Images

were taken of the temporal fossa, mandibular condyle and articular disc (Fig. 1). Samples were taken from representative lesions and normal regions of the condylar process and stored in 10% neutral buffered formalin. Bone samples were decalcified with 10% formic acid, prior to embedding in paraffin wax for sectioning.

Periodic irrigation with phosphate buffered saline (PBS) prevented the excised disc specimen from dehydrating. One disc from each tiger was processed for histology and biochemical analysis and for mechanical characterization. Immediately after dissection, samples for histology and biochemistry were collected from the caudal (C), rostral (R), medial (M), lateral (L) and central (Cent.) regions (Fig. 2). The remaining disc tissue was wrapped in gauze soaked with PBS containing protease inhibitors (10 mM *N*-ethylmaleimide and 1 mM phenylmethylsulphonyl fluoride; Sigma, St Louis, Missouri, USA) and frozen at -20°C until mechanical testing.

Histology

Serial sections (5 μm) were stained with haematoxylin and eosin (HE), picosirius red for collagen content and organization, and safranin-O for GAG content. Sections stained with picosirius red were additionally imaged under polarized light to visualize collagen organization.

Biochemistry

The mass of the samples was measured before and after a 48 h period of lyophilization. Samples were digested in 125 $\mu\text{g}/\text{ml}$ papain (Sigma) in phosphate buffer (pH 6.5) containing 2 mM *N*-acetyl cysteine (Sigma) and 2 mM EDTA for 18 h at 60°C . After digestion, no residual tissue remained. GAG content was measured with Blyscan GAG assay (Bicolor, Westbury, New York, USA), based on 1, 9-dimethylmethyl blue binding. Total collagen was quantified after hydrolyzing samples with 2 N NaOH for 20 min at 110°C using a chloramine-T hydroxyproline assay with SircolTM collagen standards (Bicolor). Cellularity was determined using the Quant-iT Picrogreen dsDNA Assay Kit (Invitrogen, Carlsbad, California, USA).

Mechanical Testing

Tensile testing was performed in the intermediate zone of the discs in the rostrocaudal and mediolateral directions (Fig. 2b). Specimens were tested according to the American Society for Testing and Materials (ASTM) D3039 standard test method (ASTM, 2008). Uniform specimens were collected using a

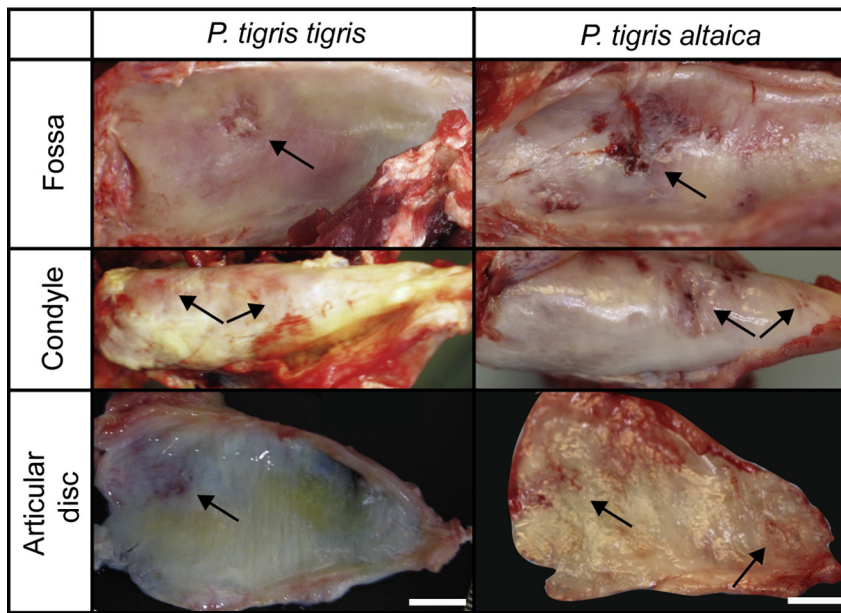


Fig. 1. TMJ gross morphology. Mandibular condyle, mandibular fossa and articular disc from the right TMJ of a Bengal and a Siberian tiger. Arrows indicate regions of degeneration. Bar, 1 cm.

rectangular cutter with a width of 2.0 mm and a length of 8.0 mm representing a length to width ratio of 4:1. The initial gauge length was considered to be the grip-to-grip length, set to 4.0 mm, representing a gauge length to gauge width of 2:1. Tensile testing was conducted using an Instron 5565 (Instron, Norwood, Massachusetts, USA). Samples were elongated at a rate of 1% strain per second (based on the initial gauge/grip-to-grip length of 4.0 mm). Stress–strain curves were generated from the load-displacement data. The load, elongation and specimen geometry data were loaded into Matlab (MathWorks, Natick, Massachusetts, USA) and analyzed with a custom program that plots load normalized to cross-sectional area and strain. User inputs identified the linear portion of the curve to determine Young’s modulus (E_Y); ultimate tensile strength (UTS) is the maximum stress experienced by the tissue.

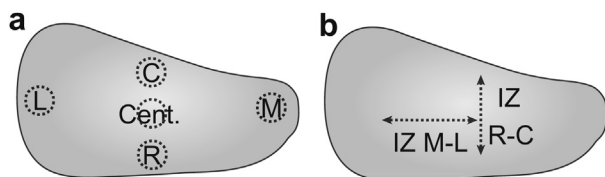


Fig. 2. Tiger TMJ disc schematic. The TMJ disc was processed for biochemical, histological and mechanical analysis. (a) Biochemical and histological specimens obtained in five disc regions: caudal (C), rostral (R), lateral (L), medial (M) and central (Cent.). (b) Tensile testing was performed through the central region in two axes: mediolateral (M–L) and rostrocaudal (R–C).

Results

Gross Morphology and Histology

The TMJs of both tigers were confirmed to have moderate to severe degenerative joint disease based on gross and histopathological observations of the mandibular condyles and gross observations of the mandibular fossa of the squamous temporal bones (Fig. 1). Grossly, areas of cartilage ulceration and erosion, as well as subchondral bone exposure, were noted in several places. Histologically, the fibrocartilage that covers the articulating surfaces of the TMJ was uneven and the osteochondral border was ill-defined (Fig. 3). The subchondral bone contained multiple cavities filled with dense to loose fibrous tissue. The subchondral bone cavities had irregular margins and occasionally contained osteoclasts within resorption lacunae. In addition, the subchondral bone was dense, with minimal trabecular bone indicating subchondral bone sclerosis. The surface of the articular zone was ragged and fibrillated. In all regions of the TMJ discs, polarized light microscopy demonstrated reduced collagen birefringence in *P. tigris altaica* compared with *P. tigris tigris* (Fig. 4).

In the rostral aspect of the disc in both tigers most collagen fibres stained bright pink and about 30% stained pale pink. In the bright pink areas, the collagen fibres showed parallel arrangement with areas of delicate waviness. In the areas of pale collagen, the fibrillar structure was ill-defined and the direction of the bundles was irregular. Multifocally embedded within the pale areas were clusters

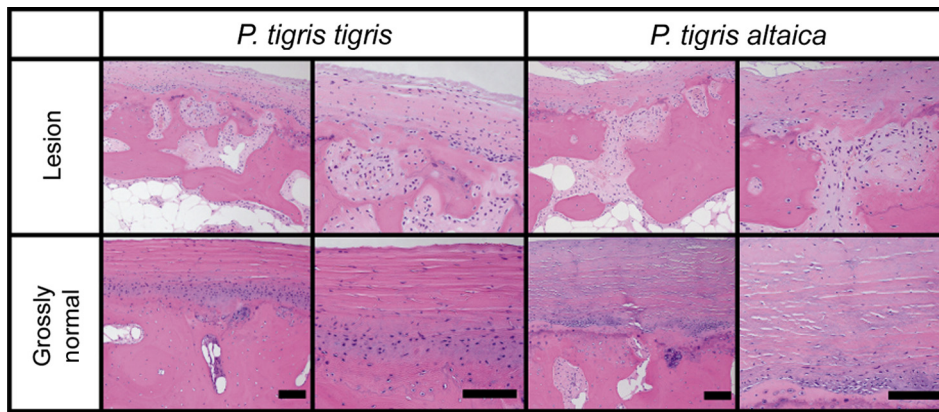


Fig. 3. Histological characterization of mandibular condyle. Histological analysis of the mandibular condyle was performed from a representative lesion and a grossly normal region for each tiger. Both tigers demonstrate regions of subchondral bone pathology and ill-defined osteochondral borders. HE. Bar, 50 μ m.

of two to five chondrocytes. These areas contained multiple clefts and were frayed. In the *P. tigris altaica* sample, there were multiple small-calibre arteries and larger-calibre congested veins rimmed by thin cuffs of pale and hypercellular collagen.

The caudal sections of the discs had linear areas of pale collagen dissected through the centre of the section by bright pink collagen. Thin streams of pale collagen branched off the main stem and dissected irregularly throughout the areas of bright pink collagen. In the *P. tigris altaica* sample, there were

additional pale collagen bundles and small aggregates of one to three chondrocytes (chondroid change) and multiple clefts between the collagen bundles.

In the central zone, there were linear areas of pale collagen alternating with areas of bright pink collagen. The fibrillar structure of the pale areas was ill-defined and cellularity was markedly higher in comparison with bright pink areas. In the *P. tigris altaica* specimen, the fibres were separated from each other by clear linear clefts. The separated fibres were arranged haphazardly and occasionally curled. Adjacent to this

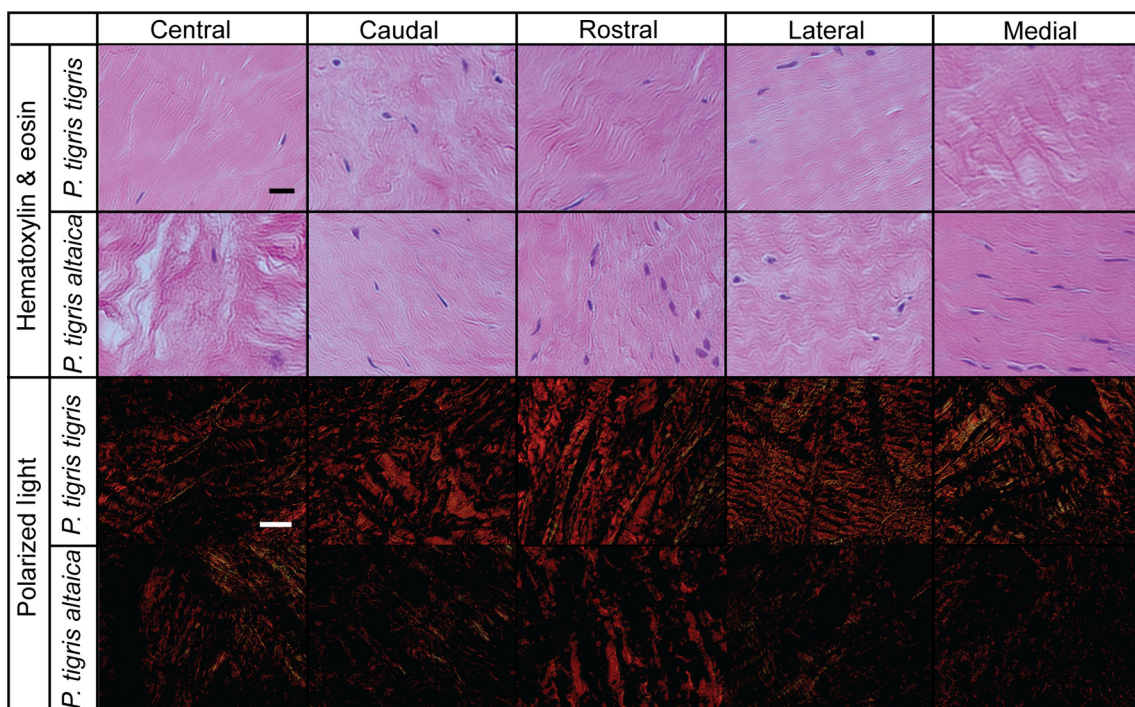


Fig. 4. Histological characterization of TMJ disc. As evidenced by HE staining and picrosirius red staining with polarized light microscopy, the collagen organization was significantly reduced in the specimen from the Siberian tiger. Bar, 100 μ m.

area there were regions of increased cellularity, slightly lighter collagen staining and few slit-like clear spaces.

The fibres in the lateral regions of the discs were uniformly bright pink with minimal cellularity. The fibres running parallel to each other formed thick bundles that regularly and orthogonally intersected other similarly arranged bundles. In the *P. tigris altaica* sample, the fibres contained alternating pale and bright pink collagen bundles. The cellularity of the pale areas was generally higher and fibre arrangement was poorly defined. One pale area contained myxomatous matrix that was cavitated by up to 10 round empty lacunae (i.e. myxomatous change rather than chondroid change).

The medial aspects of the discs contained mostly pale collagen fibres alternating with areas of bright pink collagen fibres. The fibrillar structure was not apparent in the pale fibres and their arrangement was haphazard with occasional whirling and orthogonal intersection. In the *P. tigris altaica* specimen, there were multiple small-calibre arteries and larger-calibre congested veins.

Picosirius red and safranin-O staining confirmed the disc to be fibrocartilaginous, showing intense collagen staining and minimal GAG staining across regions (data not shown). Both tigers demonstrated degeneration grossly and histologically in the bony joint components and the articular disc. Histologically, degeneration was more advanced in the TMJ of the *P. tigris altaica* (Fig. 4).

Dental Disease

Both tigers exhibited severe lesions in the dentition and dental fractures with pulp exposure (Fig. 5). The specimen from *P. tigris tigris* demonstrated a crown fracture of the right maxillary canine tooth and the specimen from *P. tigris altaica* exhibited severe abrasion at the maxillary and mandibular canine

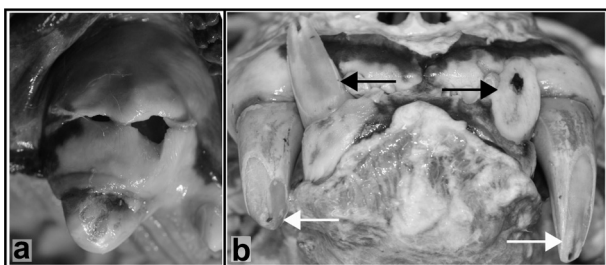


Fig. 5. Lesions in the dentition of the Bengal tiger and Siberian tiger. (a) The Bengal tiger demonstrated a complicated crown fracture of the right maxillary canine tooth with periapical lesion and fenestration through the mucosa. (b) The Siberian tiger demonstrated severe abrasion of the maxillary (white arrows) and mandibular (black arrows) canine teeth with pulp exposure. The dental lesions were indicative of chronic abnormal chewing behaviour.

teeth with pulp exposure. Although complete pertinent history with regards to chewing behaviour was not available, the dental lesions found were indicative of severe, chronic paranormal chewing behaviour.

Mechanical Properties

The mechanical properties of the TMJ discs were characterized (Fig. 6). The sample from *P. tigris tigris* demonstrated greater tensile stiffness and strength in the rostrocaudal direction compared with the mediolateral direction. The disc demonstrated stiffness of 29.50 MPa and strength of 9.77 MPa rostrocaudally and stiffness of 10.64 MPa and strength of 3.22 MPa mediolaterally. The specimen from *P. tigris altaica* did not demonstrate superior tensile properties in the rostrocaudal direction, compared with the mediolateral direction. This disc demonstrated stiffness of 7.48 MPa and strength of 2.93 MPa rostrocaudally and stiffness of 11.97 MPa and strength of 4.02 MPa mediolaterally. Thus, the disc demonstrated anisotropic tensile properties in *P. tigris tigris*, whereas tensile anisotropy was not present in *P. tigris altaica*.

Biochemical Content

The biochemical content varied between regions of the disc (Table 1). Hydration varied regionally and was greatest in both tigers in the medial and lateral

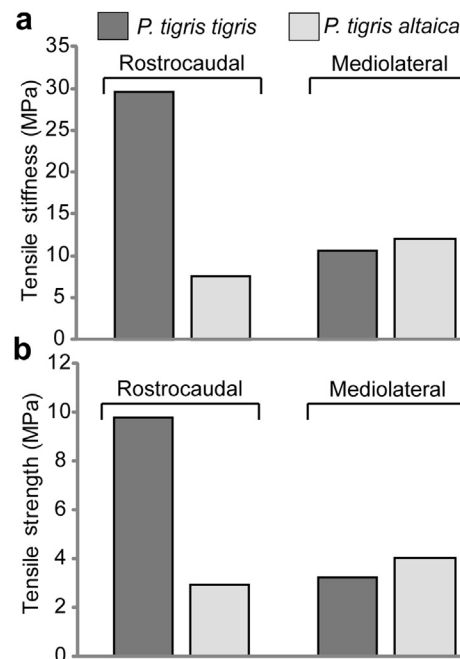


Fig. 6. Tensile properties of the TMJ disc. Biomechanical properties of the TMJ discs were tested in uniaxial tension, rostrocaudally and mediolaterally (Fig. 1). The specimen from the Bengal tiger demonstrated tensile anisotropy while that from the Siberian tiger demonstrated a loss of anisotropy in mechanical properties.

Table 1
Biochemical properties of the tiger TMJ disc

	Region	Hydration (%)	DNA/DW (%)	sGAG/DW (%)	Collagen/DW (%)
Bengal tiger	Central	72.21	0.027	0.99	62.67
	Caudal	69.91	0.088	0.59	72.70
	Rostral	75.73	0.092	0.45	68.29
	Lateral	76.38	0.042	1.07	67.24
	Medial	79.92	0.091	0.35	71.26
Siberian tiger	Central	68.98	0.043	0.96	71.36
	Caudal	73.16	0.053	1.42	61.00
	Rostral	72.71	0.091	0.37	69.27
	Lateral	77.65	0.090	0.82	70.10
	Medial	73.50	0.049	0.82	63.50

DNA, sGAG and collagen content reported per tissue dry weight.

regions. Water content ranged from 68.98 to 79.92%. The discs generally demonstrated low cellularity and <0.1% DNA by dry weight. Cellularity was greatest in samples from both tigers taken from the rostral region. The sulphated GAG (sGAG) content was also very low in the TMJ discs, on average <1% by dry weight. The discs were composed primarily of collagen with collagen content ranging from 61.27 to 71.26% by dry weight. Collagen content was greatest in the specimen from *P. tigris tigris* in the caudal region, while in the sample from *P. tigris altaica* it was lowest in the caudal region. Biochemical content varied regionally and overall demonstrated a fibrous articular disc with low cellularity.

Discussion

The aetiology of TMJ disease remains poorly understood. Efforts have been made to characterize the structure and function of the TMJ disc across species (Detamore and Athanasiou, 2003; Detamore *et al.*, 2005; Allen and Athanasiou, 2006; Singh and Detamore, 2008, 2009; Kalpakci *et al.*, 2011); however, the disc has not been characterized previously in carnivorous animals. In the present study, the TMJ was characterized histologically, biochemically and mechanically in two subspecies of tiger. Both tigers demonstrated degenerative joint disease in both the bony and soft tissue joint components. The discs reflected marked change in matrix structure, as well as reduced mechanical functionality. In the case of severe degeneration, present in the specimen from the Siberian tiger, histological, biochemical and mechanical properties reflected a loss in the functionality of the TMJ disc. With all six subspecies of tiger that remain in the wild being endangered, elucidating the pathology of TMJ disease may aid in conservation efforts and may be translatable to human health.

The essential functions of the TMJ may become compromised in the presence of degenerative joint

disease. The function of this joint is closely related to dietary requirements and cranial morphology (Nanci, 2003). The tiger has a dorsally convex mandibular condyle that fits into the ventrally concave mandibular fossa of the squamous bone. This morphology limits the joint to the exclusively hinge motion necessary for opening and closing the mouth (Perrin *et al.*, 2002). A similar morphology has been previously described in domestic cats. The domestic feline TMJ morphology is restrictive, such that independent movement of the mandible is minimal, with the exception of hinge movements (Caporn, 1995; Lantz and Verstraete, 2012). However, this motion may be compromised in the presence of joint degeneration. It was hypothesized that the tiger TMJ disc would reflect rostrocaudal fibre alignment, supporting the distribution of load through hinging motion. Furthermore, it was hypothesized that such fibre alignment would be associated with increased tensile properties in the rostrocaudal direction, compared with the mediolateral direction, reflecting mechanical anisotropy. The anticipated rostrocaudal fibre alignment and mechanical anisotropy was confirmed in the specimen from the Bengal tiger. However, moderate degenerative joint disease was confirmed grossly and histologically. In contrast, the specimen from the Siberian tiger demonstrated more advanced degenerative joint disease, confirmed grossly and histologically. In this case, compromise in fibre organization and structure and complete loss of mechanical anisotropy was observed. Degenerative joint disease may compromise essential functions of the TMJ, which normally facilitates the hinging motion of the mandible employed by carnivores.

Severe dental abrasions and tooth fractures, observed in both cases presented here, may be indicative of abnormal chewing behaviour. Additionally, the dental lesions were observed concomitantly with TMJ degeneration. An association between abnormal chewing habits and TMJ disease symptoms

has been demonstrated in man (Alamoudi, 2001; Magnusson *et al.*, 2005). Excessive or sustained physical stress may exceed the normal adaptive capacity of TMJ articular structures (Arnett *et al.*, 1996; Tanaka *et al.*, 2008; Machon *et al.*, 2011). Such behaviour may result in initiation and progression of TMJ degenerative joint disease.

Grossly and histologically, the TMJ discs of both tigers demonstrated evidence of degenerative change and compromise of fibre organization. Both discs demonstrated regions of haphazard fibre arrangement and the appearance of fibre separation. The specimen from the Siberian tiger demonstrated more severe disc degeneration. Fibres were loosely arranged and separated by clear linear clefts. The poor alignment in the regions of this specimen was further confirmed by polarized light microscopy. Histologically, the disc showed increased cellularity when compared with that from the Bengal tiger and biochemical analysis confirmed this in the central and lateral regions. Additionally, the specimen from the Bengal tiger demonstrated the presence of small-calibre arteries and large-calibre congested veins in the rostral and lateral regions, which may be indicative of degeneration (Leonardi *et al.*, 2010). Concerning degenerative joint disease, the earliest changes in osteoarthritic cartilage are characterized by a diffuse increase in cellularity, depletion of proteoglycan content (Collins, 1951; Bollet *et al.*, 1963) and loss of fibre organization (Leonardi *et al.*, 2007). With regard to disc degeneration in man, fibrosis, fibrillation, hyalinization and perforation have been reported (Wilkes, 1989). Advanced degeneration in the central region of the specimen from the Siberian tiger was reflected biochemically and histologically.

In parallel with the compromise in structure and function of the TMJ discs, the bony joint components of both tigers demonstrated gross and histological degeneration. Grossly, both the fossa and mandibular cartilage showed areas of ulceration and erosion. Histologically, the fibrocartilage of the mandibular condyles was uneven and eroded in some regions. The subchondral bone reflected degeneration with multiple cavities. While the aetiology is not understood, degeneration in the bony joint components occurred together with degeneration of the TMJ disc. Degeneration of the TMJ disc was paralleled by articular cartilage and subchondral bone degeneration in the dorsal and ventral bony joint components of both specimens.

Mechanical analysis of disc functionality demonstrated compromise of the anisotropic tensile properties when severe joint disease was present. Based on literature findings across several species and the functional demands of tiger masticatory patterns,

mechanical anisotropy was anticipated (Detamore and Athanasiou, 2003; Kalpakci *et al.*, 2011). As anticipated, the specimen from the Bengal tiger demonstrated mechanical anisotropy in the central region of the disc; the tensile properties in the rostrocaudal direction were greater than that in the mediolateral direction. However, this was not observed in the specimen from the Siberian tiger, which also showed more severe degeneration histologically. The tensile properties of the specimen from the Bengal tiger were similar in magnitude in the two directions tested. Most notably, comparing the rostrocaudal tensile properties of the two tigers, the specimen from the Bengal tiger showed 75% less stiffness and 70% less strength. Mediolaterally, there was only a 10% difference in stiffness. This discrepancy in mechanical properties parallels the previously described age-related decrease in tensile properties of articular cartilage, which peak in the third decade (Kempson, 1982). This mechanical compromise has been related to organizational changes in the collagen network, including the fibrils becoming more widely spaced, as observed histologically here, and a decrease in collagen cross linking (not quantified here). Thus, the results of the present study suggest that in the presence of severe degeneration, mechanical anisotropy of the TMJ disc is compromised.

A structure–function relationship was demonstrated in the tiger TMJ disc that was compromised in the presence of severe degenerative joint disease. Regional variations were observed in biochemical analysis that may correlate with functional loading requirements. Pathology was indicated by the loss of fibrillar structure of the disc, ultimately compromising its mechanical functionality. With all six of the remaining tiger subspecies listed as endangered, pathology of the TMJ may play an important role in the survival of these animals. Further investigation of the TMJ in healthy carnivorous animals is needed to elucidate regional variations and structure–function relationships associated with normal joint motion.

Acknowledgements

The authors thank Dr. M. Mok and Dr. S. Kubiski for providing gross dental images. This material is based on work supported by the National Science Foundation Graduate Research Fellowship under Grant No. DGE-1148897. Additionally, this work is supported by grants R01DE015038 and R01DE019666 from the National Institutes of Health.

Conflict of Interest Statement

The authors have no conflicts of interest to disclose.

References

- Alamoudi N (2001) Correlation between oral parafunction and temporomandibular disorders and emotional status among Saudi children. *Journal of Clinical Pediatric Dentistry*, **26**, 71–80.
- Allen KD, Athanasiou KA (2006) Viscoelastic characterization of the porcine temporomandibular joint disc under unconfined compression. *Journal of Biomechanics*, **39**, 312–322.
- Arnett GW, Milam SB, Gottesman L (1996) Progressive mandibular retrusion – idiopathic condylar resorption. Part I. *American Journal of Orthodontics and Dentofacial Orthopedics*, **110**, 8–15.
- Arzi B, Cissell DD, Verstraete FJ, Kass PH, Duraine GD *et al.* (2013) Computed tomographic findings in dogs and cats with temporomandibular joint disorders: 58 cases (2006–2011). *Journal of the American Veterinary Medical Association*, **242**, 69–75.
- Arzi B, Willard VP, Huey DJ, Verstraete FJM, Vapniarsky-Arzi N *et al.* (2012) The temporomandibular joint disc of Asian elephant (*Elephas maximus*) and African elephant (*Loxodonta africana*). *European Journal of Wildlife Research*, **58**, 451–459.
- ASTM. (2008) *Standard Test Method for Tensile Properties of Polymer Matrix Composite Materials*. ASTM International, West Conshohocken, p. 13.
- Bertram S, Rudisch A, Innerhofer K, Pumpel E, Grubwieser G *et al.* (2001) Diagnosing TMJ internal derangement and osteoarthritis with magnetic resonance imaging. *Journal of the American Dental Association*, **132**, 753–761.
- Bollet AJ, Handy JR, Sturgill BC (1963) Chondroitin sulfate concentration and protein-polysaccharide composition of articular cartilage in osteoarthritis. *Journal of Clinical Investigation*, **42**, 853–859.
- Caporn TM (1995) Traumatic temporomandibular joint luxation. *Veterinary and Comparative Orthopaedics and Traumatology*, **8**, 63–65.
- Collins DH (1951) The pathology of articular and spinal diseases. *Journal of Bone and Joint Surgery*, **33**, 819–820.
- Detamore MS, Athanasiou KA (2003) Tensile properties of the porcine temporomandibular joint disc. *Journal of Biomechanical Engineering*, **125**, 558–565.
- Detamore MS, Orfanos JG, Almarza AJ, French MM, Wong ME *et al.* (2005) Quantitative analysis and comparative regional investigation of the extracellular matrix of the porcine temporomandibular joint disc. *Matrix Biology*, **24**, 45–57.
- Dworkin SF, Huggins KH, LeResche L, Von Korff M, Howard J *et al.* (1990) Epidemiology of signs and symptoms in temporomandibular disorders: clinical signs in cases and controls. *Journal of the American Dental Association*, **120**, 273–281.
- Farrar WB, McCarty WL Jr. (1979) The TMJ dilemma. *Journal of the Alabama Dental Association*, **63**, 19–26.
- Kalpakci KN, Willard VP, Wong ME, Athanasiou KA (2011) An interspecies comparison of the temporomandibular joint disc. *Journal of Dental Research*, **90**, 193–198.
- Kempson GE (1982) Relationship between the tensile properties of articular cartilage from the human knee and age. *Annals of Rheumatic Disease*, **41**, 508–511.
- Lantz GC, Verstraete FJM (2012) Fractures and luxations involving the temporomandibular joint. In: *Oral and Maxillofacial Surgery in Dogs and Cats*, FJM Verstraete, MJ Lommer, Eds., Saunders, Edinburgh, pp. 321–332.
- Leonardi R, Loreto C, Barbato E, Polimeni A, Caltabiano R *et al.* (2007) A histochemical survey of the human temporomandibular joint disc of patients with internal derangement without reduction. *Journal of Craniofacial Surgery*, **18**, 1429–1433.
- Leonardi R, Rusu MC, Loreto C (2010) Temporomandibular joint disc: a proposed histopathological degeneration grading score system. *Histology and Histopathology*, **25**, 1117–1122.
- Machon V, Hirjak D, Lukas J (2011) Therapy of the osteoarthritis of the temporomandibular joint. *Journal of Cranio-Maxillo-Facial Surgery*, **39**, 127–130.
- Magnusson T, Egermarki I, Carlsson GE (2005) A prospective investigation over two decades on signs and symptoms of temporomandibular disorders and associated variables. A final summary. *Acta Odontologica Scandinavica*, **63**, 99–109.
- Nakano T, Scott PG (1989) A quantitative chemical study of glycosaminoglycans in the articular disc of the bovine temporomandibular joint. *Archives of Oral Biology*, **34**, 749–757.
- Nanci A (2003) Temporomandibular joint. In: *Ten Cate's Oral Histology, Development, Structure, and Function*, RA Ten Cate, Ed., Mosby, St Louis, pp. 376–396.
- Perrin WF, Würsig BG, Thewissen JGM (2002) *Encyclopedia of Marine Mammals*. Academic Press, San Diego, pp. xxxviii.
- Scapino RP, Obrez A, Greising D (2006) Organization and function of the collagen fiber system in the human temporomandibular joint disk and its attachments. *Cells, Tissues and Organs*, **182**, 201–225.
- Singh M, Detamore MS (2008) Tensile properties of the mandibular condylar cartilage. *Journal of Biomechanical Engineering*, **130**, 011009.
- Singh M, Detamore MS (2009) Stress relaxation behavior of mandibular condylar cartilage under high-strain compression. *Journal of Biomechanical Engineering*, **131**, 061008.
- Solberg WK, Woo MW, Houston JB (1979) Prevalence of mandibular dysfunction in young adults. *Journal of the American Dental Association*, **98**, 25–34.
- Tanaka E, Detamore MS, Mercuri LG (2008) Degenerative disorders of the temporomandibular joint: etiology, diagnosis, and treatment. *Journal of Dental Research*, **87**, 296–307.
- Wilkes CH (1989) Internal derangements of the temporomandibular joint. Pathological variations. *Archives of Otolaryngology and Head and Neck Surgery*, **115**, 469–477.

[Received, February 9th, 2013]
 [Accepted, May 8th, 2013]